

Role of pancreatography in the endoscopic management of encapsulated pancreatic collections – review and new proposed classification

Igor Mendonça Proença, Marcos Eduardo Lera dos Santos, Diogo Turiani Hourneaux de Moura, Igor Braga Ribeiro, Sergio Eiji Matuguma, Spencer Cheng, Thomas R McCarty, Epifanio Silvino do Monte Junior, Paulo Sakai, Eduardo Guimarães Hourneaux de Moura

ORCID number: Igor Mendonça Proença 0000-0003-0274-038X; Marcos Eduardo Lera dos Santos 0000-0001-9759-3807; Diogo Turiani Hourneaux de Moura 0000-0002-7446-0355; Igor Braga Ribeiro 0000-0003-1844-8973; Sergio Eiji Matuguma 0000-0002-9956-7183; Spencer Cheng 0000-0001-9584-203X; Thomas R McCarty 0000-0003-4517-5261; Epifanio Silvino do Monte Junior 0000-0001-7304-8222; Paulo Sakai 0000-0003-3088-9210; Eduardo Guimarães Hourneaux de Moura 0000-0003-1215-5731.

Author contributions: Proença IM, Dos Santos MEL, de Moura DTH, Ribeiro IB, Matuguma SE, Sakai P and de Moura EGH contributed to acquisition of data, analysis, interpretation of data, drafting the article, revising the article, final approval; Cheng S, McCarty TR and do Monte Júnior ES contributed to revising, editing and drafting article, final approval.

Conflict-of-interest statement: Dr. Moura reports personal fees from Boston Scientific, personal fees from Olympus, outside the submitted work.

Open-Access: This article is an open-access article which was

Igor Mendonça Proença, Marcos Eduardo Lera dos Santos, Diogo Turiani Hourneaux de Moura, Igor Braga Ribeiro, Sergio Eiji Matuguma, Spencer Cheng, Epifanio Silvino do Monte Junior, Paulo Sakai, Eduardo Guimarães Hourneaux de Moura, Gastrointestinal Endoscopy Unit, Department of Gastroenterology, Hospital das Clínicas, University of São Paulo, São Paulo 05403000, Brazil

Diogo Turiani Hourneaux de Moura, Thomas R McCarty, Division of Gastroenterology, Hepatology and Endoscopy, Brigham and Women's Hospital - Harvard Medical School, Boston, MA 02115, United States

Corresponding author: Igor Braga Ribeiro, MD, Research Fellow, Surgeon, Gastrointestinal Endoscopy Unit, Hospital das Clínicas da Faculdade de Medicina da Universidade de São Paulo, Av. Dr. Enéas de Carvalho Aguiar 255, Instituto Central, Prédio dos Ambulatórios, Pinheiros, São Paulo 05403000, Brazil. igorbraga1@gmail.com

Abstract

Pancreatic fluids collections are local complications related to acute or chronic pancreatitis and may require intervention when symptomatic and/or complicated. Within the last decade, endoscopic management of these collections *via* endoscopic ultrasound-guided transmural drainage has become the gold standard treatment for encapsulated pancreatic collections with high clinical success and lower morbidity compared to traditional surgery and percutaneous drainage. Proper understanding of anatomic landmarks, including assessment of the main pancreatic duct and any associated lesions – such as disruptions and strictures – are key to achieving clinical success, reducing the need for reintervention or recurrence, especially in cases with suspected disconnected pancreatic duct syndrome. Additionally, proper review of imaging and anatomic landmarks, including collection location, are pivotal to determine type and size of pancreatic stenting as well as approach using long-term transmural indwelling plastic stents. Pancreatography to adequately assess the main pancreatic duct may be performed by two methods: Either non-invasively using magnetic resonance cholangiopancreatography or endoscopically *via* retrograde cholangiopancreatography. Despite the critical need to understand anatomy *via* pancrea-

selected by an in-house editor and fully peer-reviewed by external reviewers. It is distributed in accordance with the Creative Commons Attribution Non Commercial (CC BY-NC 4.0) license, which permits others to distribute, remix, adapt, build upon this work non-commercially, and license their derivative works on different terms, provided the original work is properly cited and the use is non-commercial. See: <http://creativecommons.org/licenses/by-nc/4.0/>

Manuscript source: Invited manuscript

Specialty type: Gastroenterology and hepatology

Country/Territory of origin: Brazil

Peer-review report's scientific quality classification

Grade A (Excellent): A
Grade B (Very good): 0
Grade C (Good): C, C
Grade D (Fair): 0
Grade E (Poor): 0

Received: October 4, 2020

Peer-review started: October 4, 2020

First decision: October 27, 2020

Revised: November 8, 2020

Accepted: November 21, 2020

Article in press: November 21, 2020

Published online: December 7, 2020

P-Reviewer: Amornyotin S, Cabezuelo AS, Tsou YK

S-Editor: Zhang L

L-Editor: A

P-Editor: Ma YJ



tography and assess the main pancreatic duct, a standardized approach or uniform assessment strategy has not been described in the literature. Therefore, the aim of this review was to clarify the role of pancreatography in the endoscopic management of encapsulated pancreatic collections and to propose a new classification system to aid in proper assessment and endoscopic treatment.

Key Words: Endoscopic retrograde cholangiopancreatography; Endoscopy; Endoscopic ultrasound; Pseudocyst; Endosonography; Pancreatic ducts

©The Author(s) 2020. Published by Baishideng Publishing Group Inc. All rights reserved.

Core Tip: This review investigates the role of pancreatography in the endoscopic management of encapsulated pancreatic collections and proposes a new simplified classification system for endoscopic pancreatography findings as well as endoscopic management.

Citation: Proença IM, dos Santos MEL, de Moura DTH, Ribeiro IB, Matuguma SE, Cheng S, McCarty TR, do Monte Junior ES, Sakai P, de Moura EGH. Role of pancreatography in the endoscopic management of encapsulated pancreatic collections – review and new proposed classification. *World J Gastroenterol* 2020; 26(45): 7104-7117

URL: <https://www.wjnet.com/1007-9327/full/v26/i45/7104.htm>

DOI: <https://dx.doi.org/10.3748/wjg.v26.i45.7104>

INTRODUCTION

Pancreatic collections

Pancreatic and peripancreatic fluid collections (PFCs) are local complications due to acute or chronic pancreatitis and should be classified by the revised Atlanta Classification considering the time of presentation (more or less than 4 wk) and content (fluid alone or solid component). Before 4 wk, these collections are classified as acute, while after 4 wk collections are designated as late or chronic pancreatic collections. Once a fluid collection has become organized and developed a well-defined wall, these are then termed Encapsulated Pancreatic Collections (EPCs). EPCs are further subdivided into Pseudocyst – fluid containing only – and Walled-off Necrosis (WON) – containing the presence of fluid and a solid or necrotic content^[1]. While a majority of these collections will resolve spontaneously, especially during the early phase (< 4 wk), persistent symptoms, complications, or infection may occur prompting treatment^[2].

At present, there are 3 therapeutic approaches – surgery, percutaneous drainage and endoscopic drainage – for the treatment of EPCs, each of which may be used independently or in combination with another therapy. For many decades, surgery was considered the standard treatment modality and evolved from an open surgical technique to minimally invasive surgery, combining percutaneous drainage in a step-up manner^[3]. More recently, the development of endoscopic drainage using endoscopic ultrasound (EUS) to achieve successful transmural drainage has overcome many complications related to surgery and percutaneous drainage and has demonstrated improved efficacy safety compared to more invasive approaches. At this time, endoscopic treatment of EPCs has become the first-line therapy for both pseudocyst and WON, when technically feasible^[4,5].

Pancreatography

Since the 1970's pancreatography by Endoscopic Retrograde Cholangiopancreatography (ERCP) has been reported as a useful tool for the management of pancreatic pseudocysts. In 1979, Sugawa *et al*^[6] demonstrated pre-operative endoscopic pancreatography was a preferred strategy among 83 patients prior to surgical treatment of pseudocysts. In 1988, Nordback *et al*^[7] again reported endoscopic pancreatography to be a useful tool to guide the best approach to PFCs, one that could predict response to percutaneous drainage or surgery. Since that time, from the 1990s and 2000s, pancreatography has helped clinicians determine if an endoscopic

transpapillary approach could be performed^[8-10]. In addition to the potential therapeutic approach by transpapillary drainage, pancreatography has been reported to be an important prognostic factor to determine treatment success and recurrence, especially when Disconnected Pancreatic Duct Syndrome (DPDS) is diagnosed^[11,12]. Along with ERCP, magnetic resonance cholangiopancreatography (MRCP) has increasingly become a non-invasive alternative to assess the main pancreatic duct (MPD), especially when secretin-enhanced is available. MRCP has the additional advantage of evaluating the MPD distal to a complete disruption and the pancreatic parenchyma; however, this imaging modality continues to have a lower sensitivity when compared to endoscopic pancreatography^[13,14].

Disconnected pancreatic duct syndrome

DPDS was first described in 1989 by Smedh *et al*^[15] in a case series of three patients^[15]. It can be defined by (A) a complete MPD disruption and (B) a viable pancreatic tissue upstream from the disruption, resulting in a collection or fistula^[11,16]. Therefore, in order to properly diagnose DPDS it remains essential to adequately assess the MPD and pancreatic parenchyma, usually performed by MRCP or computerized tomography (CT) combined with ERCP. DPDS has a tremendous impact on potential treatment and prognosis of EPCs and directly affects outcomes such as clinical success, recurrence, need for repeat interventions - including surgery - and duration of hospital stay. Thus, proper recognition and diagnosis of DPDS is fundamental in order to achieve the best outcomes for EPCs^[11].

Objectives

The objective of this study was to perform a literature review including current recommendations and best practices regarding pancreatography and classifications in the context of endoscopic treatment of EPCs.

This review will be structured in to three main parts. First we aim to discuss the background information regarding pancreatography for EPCs, followed by our proposed classification, where we describe and propose a new practical and simple classification for pancreatography findings and their therapeutics implications. Lastly, we compare all previous classifications and our new proposed one and detail how this will aid endoscopists in daily practice and further improve standardization within the medical literature.

METHODS

All studies describing findings of pancreatography and the resulting endoscopic management of EPCs were included in this review. A protocolized search of MEDLINE (*via* PubMed) and Embase databases was performed through August 20, 2020.

The search strategy for MEDLINE was: “(Pancreatic duct OR Minor duodenal papilla OR Wirsung duct OR Wirsung's duct OR Cholangiopancreatography, endoscopic retrograde OR Cholangiopancreatographies, endoscopic retrograde OR ERCP) AND (Pancreatic pseudocyst OR Pancreatic pseudocysts OR Walled off necrosis)”. All types of study were included.

After the initial search, duplicate studies were removed and selected studies were examined for information including: Indication and moment of pancreatography, study modality (*i.e.*, ERCP or MRCP), pancreatography findings and descriptors, pancreatography classification, and findings that directly influenced the plan to pursue an endoscopic approach. All relevant information was extracted using Excel spreadsheets for future analysis.

BACKGROUND

Indication

Since most PFCs will resolve spontaneously, there was no indication measure to routinely evaluate the MPD. Although pancreatography is not always considered for the evaluation of EPCs, the general consensus at this time is that pancreatography should be performed for symptomatic patients with EPC that will undergo endoscopic intervention^[11,17]. Yet, despite its importance, consensus and guideline recommendations remain highly variable. Currently, the European Society Gastroin-testinal

Endoscopy (ESGE) recommends pancreatography for WON that undergo endoscopic treatment^[18]; however, there are no recommendations regarding pancreatic pseudocysts. At present, the American Society for Gastrointestinal Endoscopy does not comment on the topic or importance of pancreatography in its most recent guideline^[2]. The Asian EUS group experts guideline implicitly recommends pancreatography suggesting pancreatic duct stent for partial disruption and acknowledging higher recurrence rates among patients with MPD disruption^[19]. The rationale to evaluate the MPD *via* pancreatography – either by ERCP or MRCP – for all cases of EPCs treated endoscopically is to appropriately assess for DPDS, and to assist endoscopists as to which lesions should or may benefit from treatment^[20]. Thus, pancreatography may impact therapeutic, diagnostic, and prognostic outcomes for the management of EPCs and should always be performed in this context^[21].

Time

The decision as to when to perform pancreatography remains a highly controversial topic. Many individuals may prefer pancreatography prior to endoscopic drainage^[22], peri-procedurally at the same time as drainage^[17], or post-drainage^[23]. Authors advocating for pancreatography prior to drainage typically perform MRCP to evaluate both the collection and the MPD – allowing for information gathering, planning of the therapeutic approach, and potentially avoiding an unnecessary ERCP and complications related to it^[20,24,25]. The rationale for performing pancreatography at the same procedure as endoscopic drainage is to optimize the approach in a single procedure, which may result in a shorter hospital stay and lower overall cost^[26]. It should be noted that this approach may not be feasible in cases of gastric outlet obstruction due to inflammation which may preclude passage of duodenoscope. In regards to pancreatography post-drainage, this strategy may provide the added advantage of increased accuracy given compression by the pancreatic collection and local inflammation may limit interpretation of the MPD prior to drainage^[14,23]. Although concerns have been raised regarding ERCP in the setting of a PFC, studies have shown it to be a safe procedure with no negative impact^[17]. Presently, the ESGE recommends pancreatography, either by MRCP (preferably) or ERCP, prior to transmural stent removal after endoscopic drainage^[18]. At this time, there is no prospective study comparing the ideal strategy or time to perform pancreatography, with the decision largely driven by expert consensus, provider familiarity, anecdotal evidence, or institution protocol.

Study modality

As discussed previously, pancreatography should be performed *via* either ERCP (Supplementary Video 1) or MRCP^[27]. CT has been reported as an option to evaluation of the MPD; however, its accuracy is less than ideal and not adequate to rule out MPD lesions^[28]. Therefore, these authors do not currently recommend the use of CT to evaluate the pancreatic duct. At present, ERCP remains the gold standard to perform pancreatography due to higher sensitivity to detect ductal leaks when compared to MRCP and may be cost-effective and more convenient since it can be performed at this same time as other endoscopic procedures or drainage^[14,23]. Yet despite these advantages of ERCP, it is not without certain limitations including the invasiveness of approach and risk for complications, including pancreatitis, bleeding, and perforation – and may not be able to accurately evaluate the MPD distal to a total disruption.

MRCP has the advantage of being a non-invasive exam, without significant associated adverse events and enables investigation of the MPD distal to a complete disruption and the pancreatic parenchyma – fundamental for the diagnosis of DPDS. Furthermore secretin-enhanced MRCP has been shown to increase the sensitivity for MPD disruptions^[29]; however, this may not be widely available at most institutions. Currently, MRCP is recommended as the preferable method to evaluate the MPD after endoscopic drainage by the ESGE^[18].

More recently, EUS has also been reported to be an effective alternative method to closely provide a detailed assessment of the MPD in the context of PFCs, although the sensitivity and specificity remains poorly evaluated to date^[11,30]. Thus, these authors believe it is reasonable to perform a secretin-enhanced MRCP as the first line strategy to evaluate the pancreatic duct, if available^[20]. Otherwise endoscopic pancreatography *via* an ERCP approach should be performed as the procedure of choice with patients fully aware of the potential for adverse events, though these remain acceptably low^[17,31-34].

Descriptors

Despite the importance of pancreatography, description of findings is largely heterogeneous and not uniform in the current literature. Although some terms are often used by various authors and clinicians, terminology and descriptor language has not been standardized^[35]. The most commonly utilized terms to describe abnormalities in literature are: Disruption (some authors dived into partial/incomplete and total/complete disruptions), disconnection, DPDS, transected, leak, fistula, rupture, stricture, stenosis, cut-off, obstruction and communication/non-communication with collection^[9,13,14,18,19,22,36-40]. This heterogeneity may lead to confusion when reporting and interpreting data^[8]. Although some terms are presumed to have the same meaning - such as partial disruption and partial leak, complete disruption and disconnection, cut-off and obstruction, stricture and stenosis - others seem to be uncertain - such as disruption, rupture, transection. It is also critically important to underscore that DPDS is an incorrect term to describe endoscopic pancreatography findings. The complete disruption of the MPD is one of two necessary conditions to diagnose DPDS. An image study showing a functional pancreatic tissue upstream to the complete disruption is necessary to define DPDS^[11,40]. Therefore, ERCP alone cannot appropriately describe this phenomena; however, when pancreatography is performed by MRCP it is possible to diagnose DPDS since it allows study the MPD upstream the disruptions and the pancreatic tissue^[13].

Classifications

Five classifications on pancreatography findings have been described. The main characteristics of these classifications are summarized on [Table 1](#). One was published in India^[23], one in Italy^[35], two in the United States by the same group^[37,41] and one in Finland^[7].

The first study to classify findings on pancreatography was a Finnish retrospective study published in 1988^[7]. This group analyzed 15 patients with pancreatic pseudocysts who had undergone endoscopic pancreatography and were treated either by surgery or percutaneous external drainage. These authors then identified five patterns noted on pancreatography and classified these findings into three types, two of them with two subtypes ([Figure 1](#)). Based on the results observed, Nordback and colleagues suggested the best approach for each pancreatography type. Type I would benefit from percutaneous drainage, Type II from conservative management for 12 wk, and Type III from internal drainage (usually by surgery) or caudal pancreatic resection.

In the United States, Nealon *et al*^[37,41] published two retrospective studies in 2002 and again in 2009, showing the impact pancreatography in the context of pancreatic pseudocyst to determine the best approach and estimate prognosis^[37,41]. The second study^[37], that can be interpreted as an updated of the first one^[41], analyzed 563 patients with pseudocysts that underwent ERCP, MRCP, or contrast injection within an external drain placed percutaneous or surgically and described four pancreatography types ([Figure 2](#)). Type I findings would benefit most from endoscopic or percutaneous drainage; Type II recommending endoscopic management; and types III and IV planned for surgical intervention.

More recently, in 2017, Mutignani *et al*^[35] published a review on pancreatic fistulae and proposed a complete classification considering etiology and pancreatography, recommending an endoscopic approach for each type. These authors first divided pancreatic fistulas into three possible etiologies. Type I and type III were not related to pancreatitis and are beyond of the scope of this review. However, Type II were classified as injury to the MPD, usually related to PFCs and were dived into “open proximal stump” (IIO) and “closed proximal stump” (IIC) ([Figure 3](#)). For Type IIO, Mutignani and colleagues suggested bridging stent (first choice), transpapillary stent, or nasopancreatic drainage. For Type IIC, these authors recommended transmural EUS-drainage of the caudal collection with plastic stents, EUS-guided pancreaticogastrostomy, or a conversion to an IIO type and then treat accordingly.

In an prospective series of 88 patients with symptomatic WON, Dhir *et al*^[23] demonstrated EUS-drainage with metal stents and pancreatography was performed *via* ERCP and MRCP. This group proposed four types on pancreatography using findings of ERCP and MRCP ([Figure 4](#)) and showed higher recurrence when there was MPD disconnection, regardless of whether WON was proximal (Type I) or distal (Type II) to the disconnection.

Approach to pancreatography findings

Endoscopic approaches based upon pancreatography findings continue to be

Table 1 Classifications of pancreatography findings

Ref.	Study object	Study objective	Descriptors	Classification	Practical implication
Dhir <i>et al</i> ^[23] , 2018	EUS-drained WON	Pancreatography patters in WON and collection recurrence	-Duct disconnection; -Leaks	-Type I: Disconnection in the neck/body region, with a ductal leak at the proximal end; -Type II: Disconnected duct with a WON distal to the disconnection. It is not possible to ascertain the ductal communication of WON; -Type III: ductal leak without disconnection; -Type IV: Shows a noncommunicating WON, with no disconnection	Recurrence is higher in patters w/ disconnection (types I and II): -Type I: 5/35 patients (14.3%)–62.5% of recurrences; -Type II: 2/18 patients (11.1%) - 25% of recurrences; -Type III: 0/26 patients (0%) - 0% of recurrences; -Type IV: 1/8 patients (12.5%)–12.5% of recurrences
Mutignani <i>et al</i> ^[35] , 2017	All pancreatic fistulas	Guide endoscopic approach	-Leakages; -Disruption (partial); -Disconnection (total)	-Type I: Leakages from small side brunches. IH: head IB: body IT: tail; -Type II: Leak in the MPD Open (IIO) or Close (IIC); -Type III: leaks after pancreatectomy; IIIP: Proximal pancreas (after distal pancreatectomy); IIID: Distal pancreas (after pancreaticoduodenectomy)	-IH and IB: Bridging OR NPD; -IT: Bridging OR cianoacrilate/fibrin/ glue/ polymer injection at pancreatic tail; -IIO: Bridging OR NPD OR transpapillary stent; -IIC: EUS transmural drain of collection from excluded gland OR EUS pancreaticogastrostomy OR Conversion to IIO and treat as IIO; -IIIP: Transpapillary stent; -IIID: Few endoscopic options. EUS transmural drainage OR nasojejunal drain at the level of dehiscence in continuous aspiration
Nealon <i>et al</i> ^[37] , 2009	Pseudocyst due to pancreatitis ¹	Guide the best approach: endoscopic, interventional radiology or surgical intervention	-Normal ² ; -Stricture; -Chronic pancreatitis; -Occlusion; -Communication / no communication with collection	-Type I for normal ducts, IA: No communication, IB: With communication; -type II for duct strictures; IIA: no communication; IIB: with communication; -Type III for duct occlusion or disconnected duct syndrome; IIIA: no communication; IIIB: with communication; - Type IV for changes of chronic pancreatitis; IVA: no communication, IVB: with communication	-Type I: Endoscopic or percutaneous management; unlikely to require operation; -Type II: Endoscopic management depending on the magnitude and length of the stricture - transpapillary stents for selected ducts; -Type III and type IV: Surgical intervention exclusively
Nealon <i>et al</i> ^[41] , 2002	Pseudocyst ¹ that underwent pancreatography by ERCP	Guide the best approach between percutaneous drainage or surgical intervention	-Normal ² ; -Strictures; -Complete cutoff; -Chronic pancreatitis;-MPD-pseudocyst communication or not	-Type I: normal duct/no communication with cyst; -Type II: normal duct with duct–cyst communication; -Type III: otherwise normal duct with stricture and no duct–cyst communication; -Type IV: otherwise normal duct with stricture and duct–cyst communication; -Type V: otherwise normal duct with complete cut-off; -Type VI: chronic pancreatitis, no duct–cyst communication; -Type VII: chronic pancreatitis with duct–cyst communication	-Type I: consider percutaneous drainage (PD); -Type II: avoid PD; -Type III: consider PD treatment; -Type IV: surgery (avoid PD); -Type V: surgery (avoid PD); -Type VI: surgery (avoid PD); -Type VII: surgery (avoid PD)
Nordback <i>et al</i> ^[7] , 1988	Pseudocyst ¹ that underwent pancreatography by ERCP	Guide the best approach	-Stenosis; -Pseudocyst opens to the duct; -Pseudocyst is filled	-Type I: MPD is imaged up to the end without much stenosis, Pseudocyst may (Type IA) or may not (IB) be filled, but is further away from the main pancreatic duct; -Type II: no main duct stenosis and pseudocyst opens to the duct; -Type III: stenosis of the main pancreatic duct, + filling of the pseudocyst behind the stenosis (IIIA), or not (IIIB)	Type I: PD is a good option; Type II: expectant management for 12 wk, if persistent: Internal drainage (PD, endoscopically, surgery); Type III: Internal drainage (external drainage contraindicated); caudal resection

¹Pseudocyst before Revised Atlanta Classification could involve heterogeneous types of collections.

²“Normal duct” means duct without chronic pancreatitis changes. EUS: Endoscopic ultrasound; WON: Walled-off Necrosis; MPD: Main pancreatic duct; PD: Percutaneous drainage; NPD: Nasopancreatic drain.

controversial. Some individuals advocate transpapillary drainage *via* pancreatic stenting for all MPD leaks and disruptions and combined with transmural drainage^[20,21,23]. However, it should be noted that transpapillary drainage alone may be considered in specific cases where transmural drainage is not technically possible and there are favorable anatomical features – such as small collection, location in the head or uncinata process of the pancreas, and in cases with evidence of communication with the MPD^[12,26]. A meta-analysis including 9 studies, with a total of 604 procedures,

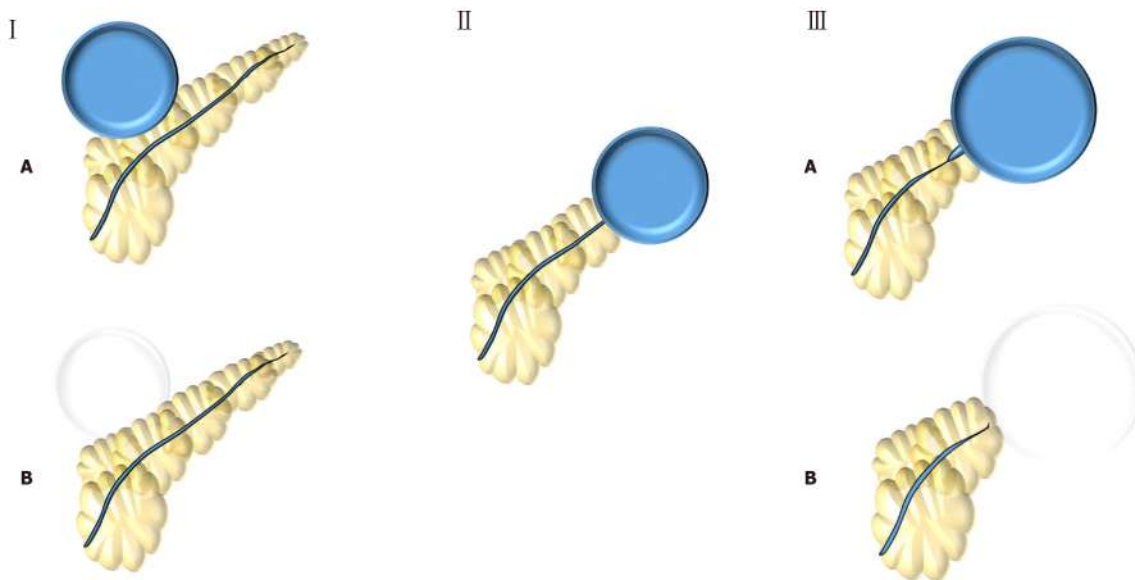


Figure 1 Nordback *et al*^[7] (1988) classification. Type I: Normal main pancreatic duct (MPD) contrasting (type IA) or not (type IB) the collection; Type II: MPD opens to the collection; Type III: MPD with stenosis contrasting (type IIIA) or not (type IIIB) the collection.

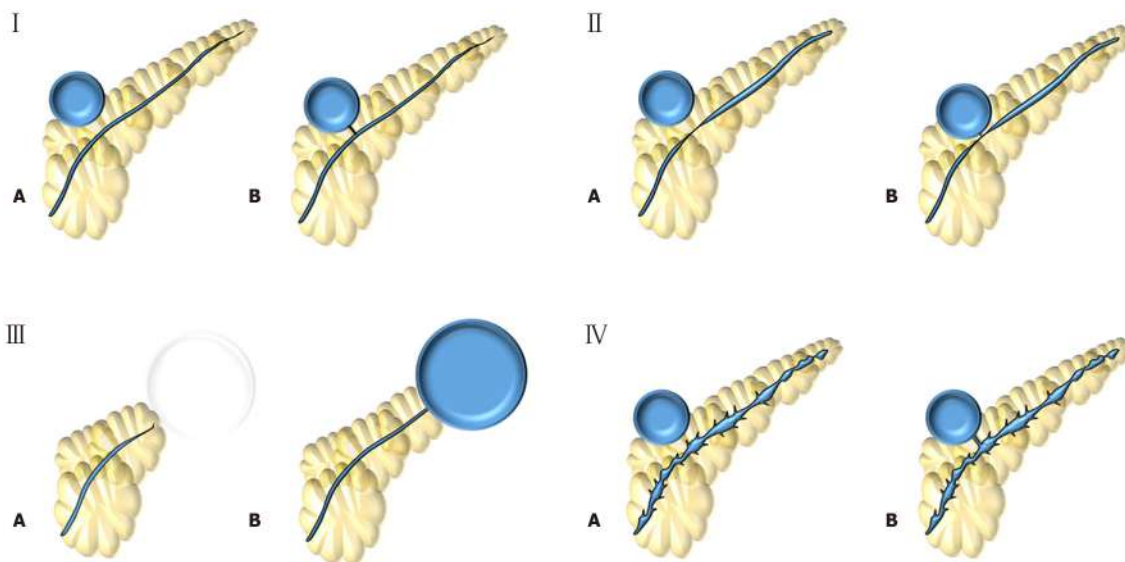


Figure 2 Nealon *et al*^[37] (2009) classification. Type I: Normal main pancreatic duct (MPD); Type II: MPD stricture; Type III: MPD occlusion; Type IV: Chronic pancreatitis. All types are subdivided according if they have communication (subtype A) or not (subtype B) with the collection.

concluded that combined drainage with transmural and transpapillary approach does not have any benefits regarding technical success, clinical success, nor recurrence when compared to transmural drainage alone^[42]. These findings are important but highly contestable since the majority (7 out of 9) of included studies were retrospective and they did not analyze the results by different pancreatography patterns. Other studies have shown better outcomes when a partial disruption have been treated by pancreatic stent bridging of the MPD^[21,43,44] with this strategy currently recommended by the Asian guidelines consensus and considered an option by ESGE^[18,19,45].

The optimal management of DPDS also remains controversial. Surgery is still the gold standard treatment, though it is associated with a considerable morbidity and cost^[46,47]. Most authors agree that pancreatic stenting is not effective for DPDS and many advocate for long-term transmural indwelling plastic stents – also recommended by ESGE^[13,18,48]. Although complications related to long-term transmural indwelling plastic stents have been reported, including migration, gastrointestinal obstruction, perforation, infection, and bleeding, these occurrences are usually mild. Thus, it is

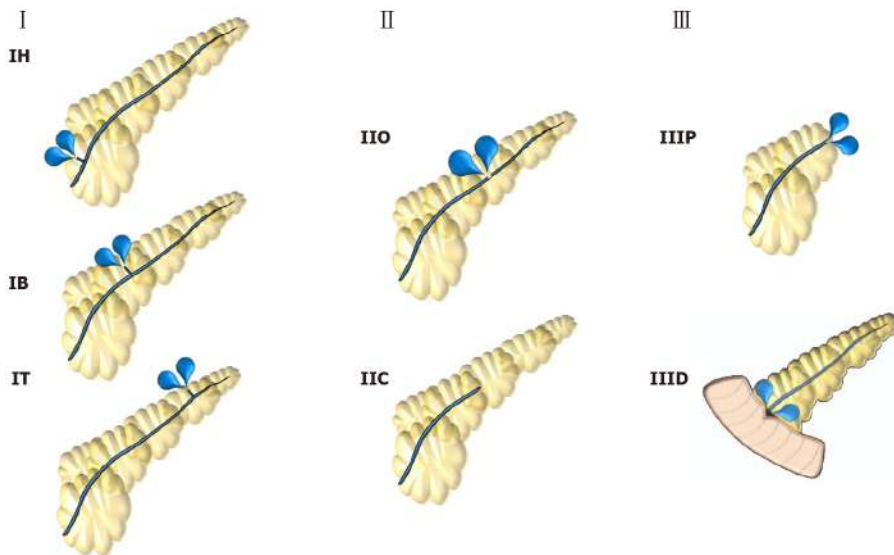


Figure 3 Mutignani *et al*^[35] (2017) classification. Type I: Leakages from small side brunches in the pancreatic head (IH), body (IB) or tail (IT); Type II: Leak in the main pancreatic duct that may have an open (IIO) or close (IIC) proximal stump; Type III: Leaks after pancreatectomy that may be after proximal pancreas (IIIP) or distal pancreas (IIID) resection.

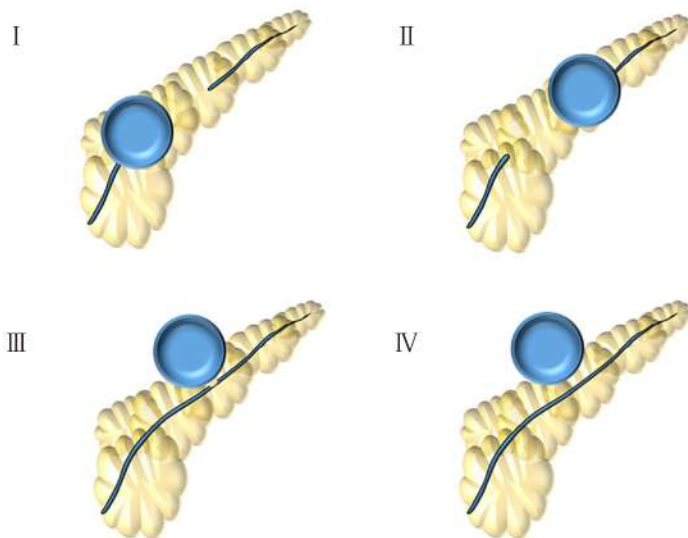


Figure 4 Dhir *et al*^[23] (2018) classification. Type I: Disconnection in the neck/body region, with a ductal leak at the proximal end; Type II: Disconnected duct with a Walled-off Necrosis distal to the disconnection – not possible to ascertain ductal communication with collection; Type III: Ductal leak without disconnection; Type IV: Shows a noncommunicating Walled-off Necrosis, with no disconnection.

considered a safe and effective method to prevent recurrence in patients with DPDS^[36,38,49]. EUS-guided transluminal-MPD drainage has been reported for external pancreatic fistulas and may be an option for selected patients with DPDS that possess a dilated MPD^[50,51]. Recently, Basha *et al*^[52] questioned the real importance of transluminal indwelling stenting for DPDS in a study with 274 patients with WON that underwent endoscopic drainage^[52]. These authors reported a recurrent rate of 13.2%, in which 97% had DPDS, but only 6.6% (17 patients) required reintervention. This study also suggested that patients with DPDS should be followed and treated if a symptomatic recurrent collection occurs instead of performing any treatment to prevent those recurrences.

Additionally, strictures of the MPD may be treated using pancreatic stenting^[8,20,28,40,53]. Although this remains a reasonable approach, there is no comparative study demonstrating the impact of stricture treatment for EPCs management. Currently, the lack of prospective controlled studies comparing the role of pancreatography findings makes most the current recommendations weak with an

overall low-quality of evidence. Therefore, it is necessary to standardize pancreatography findings for better communication and to enable high-quality prospective controlled studies considering those different findings in order to clarify the best endoscopic management towards MPD injuries in the context of EPCs.

NEW CLASSIFICATION PROPOSITION

The classifications found in the literature, despite having value, are burdensome, overly complex, and difficult to apply during routine examinations. Therefore, the translation of these schemes to real-world clinical practice, or even standard for research reporting purposes has remained limited. As such, designing a simple, practical, and applicable classification system to standardize endoscopic pancreatography findings in the context of endoscopic treatment of EPCs is needed. Here we propose a new easy to apply classification for endoscopic pancreatography findings (Figure 5) with translation of these findings to impact endoscopic management (Table 2).

Type I involves a normal MPD, without stricture or disruption (Figure 6A). Therefore, no additional therapy is required. Type II demonstrates a stricture within the MPD (Figure 6B). We recommend treatment involving a pancreatic stent through the area of stenosis. Type III involves a partial disruption of the MPD – the MPD contrasts beyond disruption point (Figure 6C). In these cases, pancreatic stent bridging the rupture should be performed. Type IV shows a complete disruption of the MPD – the MPD does not contrast beyond disruption point. It may be presented with contrast extravasation (Type IV-A) (Figure 6D) or without contrast extravasation and abrupt cut-off (Type IV-B) (Figure 6E). Type IV should alert for the possibility of DPSP and an image study - such as CT or MRI - must be performed to confirm or rule out DPDS. If DPSP is confirmed, long-term transmural indwelling plastic stents should be considered. It is also critically important to recognize that more than one type may be presented simultaneously, such as a pancreatography demonstrating a stricture and a complete disruption with contrast extravasation (Figure 6F) - classified as a type II + IV-A.

DISCUSSION

Classifications are important tools used frequently in all fields of medicine, helping to categorize finding, standardize treatment-specific approaches, and facilitate ease of communication between providers. Furthermore, the better the attempt at classification (*i.e.*, the ability for conditions to fit within pre-determined criteria), the more applicable and clinically relevant these can be to everyday clinical practice. Reviewing literature, there is not any current classification system allow for this to occur – further highlighting why no descriptions and increased confusion regarding the role of pancreatography is present in the literature.

It is well established that EUS-guided transmural drainage is the gold standard approach for both pseudocyst and WON^[4,5]. Thus, pancreatography classifications that attempt to guide the best approach – surgery, percutaneous drainage, or endoscopic drainage - no longer have clinical relevance. At present, there is not sufficient evidence or data in the proposed classifications by Nordback^[7] and Nealon^[37,41], to guide clinicians and endoscopists regarding the best approach decision.

Since EUS-drainage is the gold standard treatment for EPCs, pancreatography classification should ultimately be used to determine the best endoscopic approach. Mutignani's classification^[35] is the only one among the previous classification systems that attempts to guide endoscopic approach accordingly to the findings. Yet despite this, limitations remain.

The endoscopic approaches towards MPD remain controversial in literature since there is no prospective randomized trial comparing the decision to treat MPD lesions. While some retrospective studies and case series suggest better outcomes when a partial disruption of the MPD is treated with a bridging pancreatic stent^[12,21,43,44], this data has not yet been studied in prospective studies. Additionally, another important point is to distinguish between a partial and a complete disruption of the MPD. Only the system devised by Dhir *et al*^[23] dedicated a specific category (type III) for partial disruption of the MPD.

DPDS has been reported as an important condition that is underdiagnosed – related to an increased need for reintervention, surgery, longer hospital stay, and higher

Table 2 Lera-Proença new proposed classification for endoscopic pancreatography findings

Types	Finding	Endoscopic approaches
Type I	Normal MPD	No additional therapy
Type II	Stricture	Consider pancreatic stent
Type III	Partial disruption (MPD contrasts beyond disruption point)	Pancreatic stent bridging the rupture
Type IV	Complete disruption (MPD does not contrast beyond disruption point), A: With contrast extravasation; B: Without contrast extravasation and abrupt cut-off	CT or MRI to confirm or rule out DPDS; Consider long-term transmural indwelling plastic stents

MPD: Main pancreatic duct, CT: Computerized tomography; MRI: Magnetic resonance imaging; DPDS: Disconnected pancreatic duct syndrome.

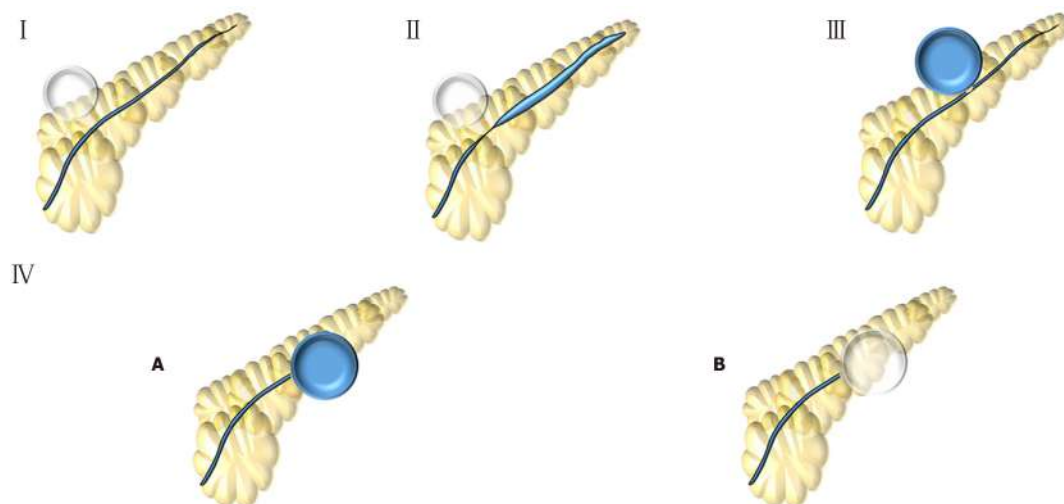


Figure 5 Lera-Proença (2020) new proposed classification. Type I: Normal main pancreatic duct; Type II: Stricture; Type III: Partial disruption – main pancreatic duct contrasts beyond disruption; Type IV: Complete disruption - main pancreatic duct does not contrast beyond disruption. IV-A: with contrast extravasation or IV-B: without contrast extravasation and cut-off.

recurrence^[11,48]. Therefore, it remains essential that any pancreatography classification define and categorize lesions with increased ability to differentiate and diagnose DPDS. Among previous classifications, Dhir's^[23] was the only one to correlated properly pancreatography findings and DPDS.

Our new proposed classification aims to determine the best endoscopic treatment based upon pancreatography findings, clearly distinguish between partial and total disruption and suggests cases which should warrant investigation for DPDS. Additionally, this classification system as designed by these authors is based upon endoscopic pancreatography findings, making it easier and more applicable than Dhir's classification that requires additionally imaging with MRCP. A comparative table between all classifications and the crucial points is presented in [Table 3](#).

CONCLUSION

Evaluation of the MPD *via* pancreatography in the context of endoscopic treatment of EPCs may provide diagnostic, therapeutic, and prognostic implications and should therefore be performed for all cases. This may be performed by ERCP or MRCP, preferably with contrast-enhanced secretin when available. While optimal timing (pre-drainage, peri-drainage, or post-drainage) has not been determined, assessment of the duct, regardless of when, remains key. Although some pancreatography classification have been proposed, none is widely used in literature, likely due to non-standardized approaches or outdated practices not relevant to the modern endoscopist for the management of EPCs. Additionally, it is critically important to understand the significance of DPDS, make a clear distinction between partial and complete MPD disruption, and determine the best endoscopic approach based upon pancreatography

Table 3 Comparison between pancreatography classifications

Ref.	Study modality	Guide endoscopic approach?	Category for partial MPD disruption?	Diagnosis or suspicion of DPDS?
Proença, 2020	ERCP	Yes	Yes	Yes
Dhir <i>et al</i> ^[23] , 2018	ERCP + MRCP	No	Yes	Yes
Mutignani <i>et al</i> ^[35] , 2017	Not specified	Yes	No	No
Nealon <i>et al</i> ^[37] , 2009	ERCP	No	No	No
Nordback <i>et al</i> ^[7] , 1988	ERCP	No	No	No

ERCP: Endoscopic retrograde cholangiopancreatography; MRCP: Magnetic resonance cholangiopancreatography; MPD: Main pancreatic duct; DPDS: Disconnected Pancreatic Duct Syndrome.

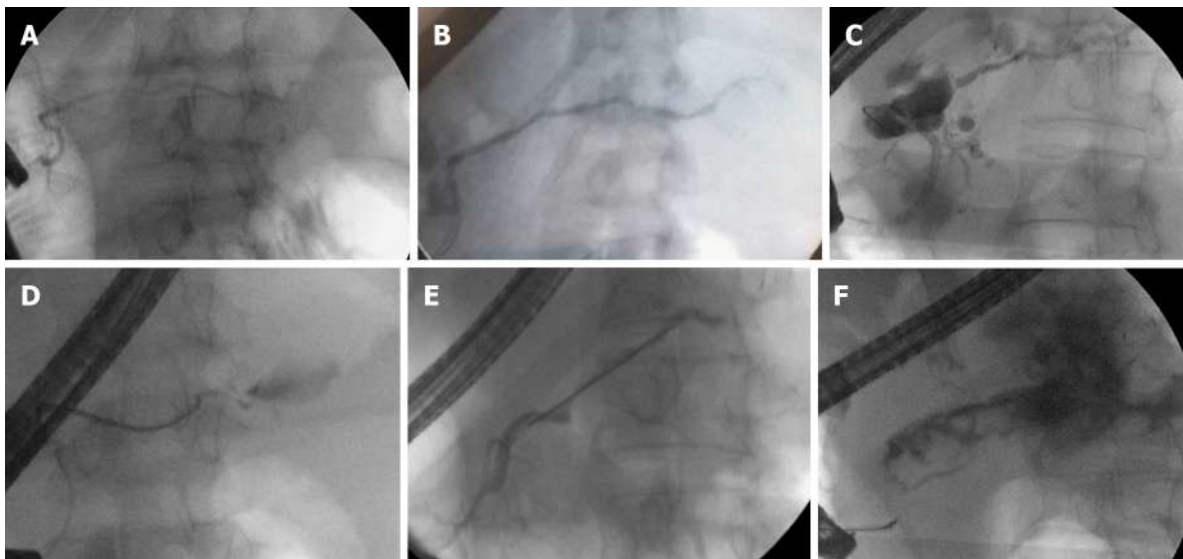


Figure 6 Endoscopic pancreatography classified by Lera-Proença classification. Endoscopic pancreatography findings, A: Normal pancreatography (type I); B: Stricture (type II); C: Partial disruption (type III); D: Complete disruption with contrast extravasation (type IV-A); E: Complete disruption without contrast extravasation and cut-off (Type IV-B); and F: Stricture and complete disruption with contrast extravasation (Type II + IV-A).

findings. Therefore, we propose a simplified and practical classification system to report the findings of pancreatography, improve uniformity for future research, inform guidelines and clinical management, and ultimately guide endoscopic treatment of EPCs.

REFERENCES

- Banks PA**, Bollen TL, Dervenis C, Gooszen HG, Johnson CD, Sarr MG, Tsiotos GG, Vege SS; Acute Pancreatitis Classification Working Group. Classification of acute pancreatitis--2012: revision of the Atlanta classification and definitions by international consensus. *Gut* 2013; **62**: 102-111 [PMID: 23100216 DOI: 10.1136/gutjnl-2012-302779]
- ASGE Standards of Practice Committee**, Muthusamy VR, Chandrasekhara V, Acosta RD, Bruining DH, Chathadi KV, Eloubeidi MA, Faulx AL, Fonkalsrud L, Gurudu SR, Khashab MA, Kothari S, Lightdale JR, Pasha SF, Saltzman JR, Shaukat A, Wang A, Yang J, Cash BD, DeWitt JM. The role of endoscopy in the diagnosis and treatment of inflammatory pancreatic fluid collections. *Gastrointest Endosc* 2016; **83**: 481-488 [PMID: 26796695 DOI: 10.1016/j.gie.2015.11.027]
- van Santvoort HC**, Besselink MG, Bakker OJ, Hofker HS, Boermeester MA, Dejong CH, van Goor H, Schaapherder AF, van Eijck CH, Bollen TL, van Ramshorst B, Nieuwenhuijs VB, Timmer R, Laméris JS, Kruijff PM, Manusama ER, van der Harst E, van der Schelling GP, Karsten T, Hesselink EJ, van Laarhoven CJ, Rosman C, Bosscha K, de Wit RJ, Houdijk AP, van Leeuwen MS, Buskens E, Gooszen HG; Dutch Pancreatitis Study Group. A step-up approach or open necrosectomy for

- necrotizing pancreatitis. *N Engl J Med* 2010; **362**: 1491-1502 [PMID: [20410514](#) DOI: [10.1056/NEJMoa0908821](#)]
- 4 **Farias GFA**, Bernardo WM, De Moura DTH, Guedes HG, Brunaldi VO, Visconti TAC, Gonçalves CVT, Sakai CM, Matuguma SE, Santos MELD, Sakai P, De Moura EGH. Endoscopic versus surgical treatment for pancreatic pseudocysts: Systematic review and meta-analysis. *Medicine (Baltimore)* 2019; **98**: e14255 [PMID: [30813129](#) DOI: [10.1097/MD.00000000000014255](#)]
 - 5 **Bang JY**, Wilcox CM, Arnoletti JP, Varadarajulu S. Superiority of endoscopic interventions over minimally invasive surgery for infected necrotizing pancreatitis: meta-analysis of randomized trials. *Dig Endosc* 2020; **32**: 298-308 [PMID: [31220368](#) DOI: [10.1111/den.13470](#)]
 - 6 **Sugawa C**, Walt AJ. Endoscopic retrograde pancreatography in the surgery of pancreatic pseudocysts. *Surgery* 1979; **86**: 639-647 [PMID: [483173](#)]
 - 7 **Nordback I**, Auvinen O, Airo I, Isolauri J, Teerenhovi O. ERCP in evaluating the mode of therapy in pancreatic pseudocyst. *HPB Surg* 1988; **1**: 35-44 [PMID: [3153775](#) DOI: [10.1155/1988/47060](#)]
 - 8 **Devière J**, Bueso H, Baize M, Azar C, Love J, Moreno E, Cremer M. Complete disruption of the main pancreatic duct: endoscopic management. *Gastrointest Endosc* 1995; **42**: 445-451 [PMID: [8566636](#) DOI: [10.1016/S0016-5107\(95\)70048-X](#)]
 - 9 **Traverso LW**, Kozarek RA. Interventional management of peripancreatic fluid collections. *Surg Clin North Am* 1999; **79**: 745-757, viii-viix [PMID: [10470324](#) DOI: [10.1016/S0039-6109\(05\)70040-2](#)]
 - 10 **Teoh AY**, Ho LK, Dhir VK, Jin ZD, Kida M, Seo DW, Wang HP, Yang AM, Binmoeller KF, Varadarajulu S. A multi-institutional survey on the practice of endoscopic ultrasound (EUS) guided pseudocyst drainage in the Asian EUS group. *Endosc Int Open* 2015; **3**: E130-E133 [PMID: [26135654](#) DOI: [10.1055/s-0034-1390890](#)]
 - 11 **Bang JY**, Wilcox CM, Navaneethan U, Hasan MK, Peter S, Christein J, Hawes R, Varadarajulu S. Impact of Disconnected Pancreatic Duct Syndrome on the Endoscopic Management of Pancreatic Fluid Collections. *Ann Surg* 2018; **267**: 561-568 [PMID: [27849658](#) DOI: [10.1097/SLA.0000000000002082](#)]
 - 12 **Smoczyński M**, Jagielski M, Jabłońska A, Adrych K. Transpapillary drainage of walled-off pancreatic necrosis - a single center experience. *Wideochir Inne Tech Maloinwazyjne* 2016; **10**: 527-533 [PMID: [26865888](#) DOI: [10.5114/wiitm.2015.55677](#)]
 - 13 **Varadarajulu S**, Rana SS, Bhasin DK. Endoscopic therapy for pancreatic duct leaks and disruptions. *Gastrointest Endosc Clin N Am* 2013; **23**: 863-892 [PMID: [24079795](#) DOI: [10.1016/j.giec.2013.06.008](#)]
 - 14 **Peng R**, Zhang XM, Ji YF, Chen TW, Yang L, Huang XH, Chi XX. Pancreatic duct patterns in acute pancreatitis: a MRI study. *PLoS One* 2013; **8**: e72792 [PMID: [24015276](#) DOI: [10.1371/journal.pone.0072792](#)]
 - 15 **Smedh K**, Larsson J, Lindström E, Ihse I. Late sequelae of central pancreatic necrosis. Case report. *Acta Chir Scand* 1989; **155**: 553-555 [PMID: [2603612](#)]
 - 16 **Tann M**, Maglinte D, Howard TJ, Sherman S, Fogel E, Madura JA, Lehman GA. Disconnected pancreatic duct syndrome: imaging findings and therapeutic implications in 26 surgically corrected patients. *J Comput Assist Tomogr* 2003; **27**: 577-582 [PMID: [12886147](#) DOI: [10.1097/00004728-200307000-00023](#)]
 - 17 **Tyberg A**, Karia K, Gabr M, Desai A, Doshi R, Gaidhane M, Sharaiha RZ, Kahaleh M. Management of pancreatic fluid collections: A comprehensive review of the literature. *World J Gastroenterol* 2016; **22**: 2256-2270 [PMID: [26900288](#) DOI: [10.3748/wjg.v22.i7.2256](#)]
 - 18 **Arvanitakis M**, Dumonceau JM, Albert J, Badaoui A, Bali MA, Barthet M, Besselink M, Deviere J, Oliveira Ferreira A, Gyökeres T, Hritz I, Hucl T, Milashka M, Papanikolaou IS, Poley JW, Seewald S, Vanbiervliet G, van Lienden K, van Santvoort H, Voermans R, Delhaye M, van Hooft J. Endoscopic management of acute necrotizing pancreatitis: European Society of Gastrointestinal Endoscopy (ESGE) evidence-based multidisciplinary guidelines. *Endoscopy* 2018; **50**: 524-546 [PMID: [29631305](#) DOI: [10.1055/a-0588-5365](#)]
 - 19 **Teoh AYB**, Dhir V, Kida M, Yasuda I, Jin ZD, Seo DW, Almadi M, Ang TL, Hara K, Hilmi I, Itoi T, Lakhtakia S, Matsuda K, Pausawasdi N, Puri R, Tang RS, Wang HP, Yang AM, Hawes R, Varadarajulu S, Yasuda K, Ho LKY. Consensus guidelines on the optimal management in interventional EUS procedures: results from the Asian EUS group RAND/UCLA expert panel. *Gut* 2018; **67**: 1209-1228 [PMID: [29463614](#) DOI: [10.1136/gutjnl-2017-314341](#)]
 - 20 **Xu MM**, Andalib I, Novikov A, Dawod E, Gabr M, Gaidhane M, Tyberg A, Kahaleh M. Endoscopic Therapy for Pancreatic Fluid Collections: A Definitive Management Using a Dedicated Algorithm. *Clin Endosc* 2020; **53**: 355-360 [PMID: [31794655](#) DOI: [10.5946/ce.2019.113](#)]
 - 21 **Jagielski M**, Smoczyński M, Adrych K. The role of endoscopic treatment of pancreatic duct disruption in patients with walled-off pancreatic necrosis. *Surg Endosc* 2018; **32**: 4939-4952 [PMID: [29869080](#) DOI: [10.1007/s00464-018-6255-4](#)]
 - 22 **Bang JY**, Wilcox CM, Trevino JM, Ramesh J, Hasan M, Hawes RH, Varadarajulu S. Relationship between stent characteristics and treatment outcomes in endoscopic transmural drainage of uncomplicated pancreatic pseudocysts. *Surg Endosc* 2014; **28**: 2877-2883 [PMID: [24789132](#) DOI: [10.1007/s00464-014-2877-2](#)]

- 10.1007/s00464-014-3541-7]
- 23 **Dhir V**, Adler DG, Dalal A, Aherrao N, Shah R, Maydeo A. Early removal of biflanged metal stents in the management of pancreatic walled-off necrosis: a prospective study. *Endoscopy* 2018; **50**: 597-605 [PMID: 29272904 DOI: 10.1055/s-0043-123575]
 - 24 **Funari MP**, Ribeiro IB, de Moura DTH, Bernardo WM, Brunaldi VO, Rezende DT, Resende RH, de Marco MO, Franzini TAP, de Moura EGH. Adverse events after biliary sphincterotomy: Does the electric current mode make a difference? A systematic review and meta-analysis of randomized controlled trials. *Clin Res Hepatol Gastroenterol* 2020; **44**: 739-752 [PMID: 32088149 DOI: 10.1016/j.clinre.2019.12.009]
 - 25 **Matsubayashi CO**, Ribeiro IB, de Moura DTH, Brunaldi VO, Bernardo WM, Hathorn KE, de Moura EGH. Is Endoscopic Balloon Dilation Still Associated With Higher Rates of Pancreatitis?: A Systematic Review and Meta-Analysis. *Pancreas* 2020; **49**: 158-174 [PMID: 32049951 DOI: 10.1097/MPA.0000000000001489]
 - 26 **Shah A**, Denicola R, Edirisuriya C, Siddiqui AA. Management of Inflammatory Fluid Collections and Walled-Off Pancreatic Necrosis. *Curr Treat Options Gastroenterol* 2017; **15**: 576-586 [PMID: 29103188 DOI: 10.1007/s11938-017-0161-z]
 - 27 **Andalib I**, Dawod E, Kahaleh M. Modern Management of Pancreatic Fluid Collections. *J Clin Gastroenterol* 2018; **52**: 97-104 [PMID: 29095421 DOI: 10.1097/MCG.0000000000000940]
 - 28 **Kamal A**, Singh VK, Akshintala VS, Kawamoto S, Tsai S, Haider M, Fishman EK, Kamel IR, Zaheer A. CT and MRI assessment of symptomatic organized pancreatic fluid collections and pancreatic duct disruption: an interreader variability study using the revised Atlanta classification 2012. *Abdom Imaging* 2015; **40**: 1608-1616 [PMID: 25425489 DOI: 10.1007/s00261-014-0303-x]
 - 29 **Sherman S**, Freeman ML, Tarnasky PR, Wilcox CM, Kulkarni A, Aisen AM, Jacoby D, Kozarek RA. Administration of secretin (RG1068) increases the sensitivity of detection of duct abnormalities by magnetic resonance cholangiopancreatography in patients with pancreatitis. *Gastroenterology* 2014; **147**: 646-654.e2 [PMID: 24906040 DOI: 10.1053/j.gastro.2014.05.035]
 - 30 **de Moura DTH**, Ryou M, de Moura EGH, Ribeiro IB, Bernardo WM, Thompson CC. Endoscopic Ultrasound-Guided Fine Needle Aspiration and Endoscopic Retrograde Cholangiopancreatography-Based Tissue Sampling in Suspected Malignant Biliary Strictures: A Meta-Analysis of Same-Session Procedures. *Clin Endosc* 2020; **53**: 417-428 [PMID: 31684700 DOI: 10.5946/ce.2019.053]
 - 31 **Guacho JAL**, de Moura DTH, Ribeiro IB, da Ponte Neto AM, Singh S, Tucci MGB, Bernardo WM, de Moura EGH. Propofol vs midazolam sedation for elective endoscopy in patients with cirrhosis: A systematic review and meta-analysis of randomized controlled trials. *World J Gastrointest Endosc* 2020; **12**: 241-255 [PMID: 32879659 DOI: 10.4253/wjge.v12.i8.241]
 - 32 **Delgado AAA**, de Moura DTH, Ribeiro IB, Bazarbashi AN, Dos Santos MEL, Bernardo WM, de Moura EGH. Propofol vs traditional sedatives for sedation in endoscopy: A systematic review and meta-analysis. *World J Gastrointest Endosc* 2019; **11**: 573-588 [PMID: 31839876 DOI: 10.4253/wjge.v11.i12.573]
 - 33 **de Oliveira PVAG**, de Moura DTH, Ribeiro IB, Bazarbashi AN, Franzini TAP, Dos Santos MEL, Bernardo WM, de Moura EGH. Efficacy of digital single-operator cholangioscopy in the visual interpretation of indeterminate biliary strictures: a systematic review and meta-analysis. *Surg Endosc* 2020; **34**: 3321-3329 [PMID: 32342216 DOI: 10.1007/s00464-020-07583-8]
 - 34 **Galetti F**, Moura DTH, Ribeiro IB, Funari MP, Coronel M, Sachde AH, Brunaldi VO, Franzini TP, Bernardo WM, Moura EGH. Cholangioscopy-guided lithotripsy vs. conventional therapy for complex bile duct stones: a systematic review and meta-analysis. *Arq Bras Cir Dig* 2020; **33**: e1491 [PMID: 32609255 DOI: 10.1590/0102-672020190001e1491]
 - 35 **Mutignani M**, Dokas S, Tringali A, Forti E, Pugliese F, Cintolo M, Manta R, Dioscoridi L. Pancreatic Leaks and Fistulae: An Endoscopy-Oriented Classification. *Dig Dis Sci* 2017; **62**: 2648-2657 [PMID: 28780610 DOI: 10.1007/s10620-017-4697-5]
 - 36 **Yamauchi H**, Iwai T, Kida M, Okuwaki K, Kurosu T, Watanabe M, Adachi K, Tadehara M, Imaizumi H, Koizumi W. Complications of Long-Term Indwelling Transmural Double Pigtail Stent Placement for Symptomatic Peripancreatic Fluid Collections. *Dig Dis Sci* 2019; **64**: 1976-1984 [PMID: 30725302 DOI: 10.1007/s10620-019-05508-7]
 - 37 **Nealon WH**, Bhutani M, Riall TS, Raju G, Ozkan O, Neilan R. A unifying concept: pancreatic ductal anatomy both predicts and determines the major complications resulting from pancreatitis. *J Am Coll Surg* 2009; **208**: 790-9; discussion 799-801 [PMID: 19476839 DOI: 10.1016/j.jamcollsurg.2008.12.027]
 - 38 **Arvanitakis M**, Delhaye M, Bali MA, Matos C, De Maertelaer V, Le Moine O, Devière J. Pancreatic-fluid collections: a randomized controlled trial regarding stent removal after endoscopic transmural drainage. *Gastrointest Endosc* 2007; **65**: 609-619 [PMID: 17324413 DOI: 10.1016/j.gie.2006.06.083]
 - 39 **Larsen M**, Kozarek RA. Management of Disconnected Pancreatic Duct Syndrome. *Curr Treat Options Gastroenterol* 2016; **14**: 348-359 [PMID: 27392638 DOI: 10.1007/s11938-016-0098-7]
 - 40 **Tonolini M**, Bareggi E, Gambitta P. Advanced endoscopic interventions on the pancreas and

- pancreatic ductal system: a primer for radiologists. *Insights Imaging* 2019; **10**: 5 [PMID: 30689070 DOI: 10.1186/s13244-019-0689-7]
- 41 **Nealon WH**, Walser E. Main pancreatic ductal anatomy can direct choice of modality for treating pancreatic pseudocysts (surgery versus percutaneous drainage). *Ann Surg* 2002; **235**: 751-758 [PMID: 12035030 DOI: 10.1097/0000658-200206000-00001]
 - 42 **Amin S**, Yang DJ, Lucas AL, Gonzalez S, DiMaio CJ. There Is No Advantage to Transpapillary Pancreatic Duct Stenting for the Transmural Endoscopic Drainage of Pancreatic Fluid Collections: A Meta-Analysis. *Clin Endosc* 2017; **50**: 388-394 [PMID: 28415167 DOI: 10.5946/ce.2016.091]
 - 43 **Varadarajulu S**, Noone TC, Tutuiian R, Hawes RH, Cotton PB. Predictors of outcome in pancreatic duct disruption managed by endoscopic transpapillary stent placement. *Gastrointest Endosc* 2005; **61**: 568-575 [PMID: 15812410 DOI: 10.1016/S0016-5107(04)02832-9]
 - 44 **Telford JJ**, Farrell JJ, Saltzman JR, Shields SJ, Banks PA, Lichtenstein DR, Johannes RS, Kelsey PB, Carr-Locke DL. Pancreatic stent placement for duct disruption. *Gastrointest Endosc* 2002; **56**: 18-24 [PMID: 12085030 DOI: 10.1067/mge.2002.125107]
 - 45 **Isayama H**, Nakai Y, Rerknimitr R, Khor C, Lau J, Wang HP, Seo DW, Ratanachu-Ek T, Lakhtakia S, Ang TL, Ryozaawa S, Hayashi T, Kawakami H, Yamamoto N, Iwashita T, Itokawa F, Kuwatani M, Kitano M, Hanada K, Kogure H, Hamada T, Ponnudurai R, Moon JH, Itoi T, Yasuda I, Irisawa A, Maetani I. Asian consensus statements on endoscopic management of walled-off necrosis. Part 2: Endoscopic management. *J Gastroenterol Hepatol* 2016; **31**: 1555-1565 [PMID: 27042957 DOI: 10.1111/jgh.13398]
 - 46 **Maatman TK**, Roch AM, Lewellen KA, Heimberger MA, Ceppa EP, House MG, Nakeeb A, Schmidt CM, Zyromski NJ. Disconnected Pancreatic Duct Syndrome: Spectrum of Operative Management. *J Surg Res* 2020; **247**: 297-303 [PMID: 31685250 DOI: 10.1016/j.jss.2019.09.068]
 - 47 **Szentes MJ**, Traverso LW, Kozarek RA, Freeny PC. Invasive treatment of pancreatic fluid collections with surgical and nonsurgical methods. *Am J Surg* 1991; **161**: 600-605 [PMID: 2031545 DOI: 10.1016/0002-9610(91)90909-W]
 - 48 **Rana SS**, Bhasin DK, Sharma R, Gupta R. Factors determining recurrence of fluid collections following migration of intended long term transmural stents in patients with walled off pancreatic necrosis and disconnected pancreatic duct syndrome. *Endosc Ultrasound* 2015; **4**: 208-212 [PMID: 26374578 DOI: 10.4103/2303-9027.162999]
 - 49 **Varadarajulu S**, Wilcox CM. Endoscopic placement of permanent indwelling transmural stents in disconnected pancreatic duct syndrome: does benefit outweigh the risks? *Gastrointest Endosc* 2011; **74**: 1408-1412 [PMID: 21981812 DOI: 10.1016/j.gie.2011.07.049]
 - 50 **Will U**, Fueeldner F, Goldmann B, Mueller AK, Wanzar I, Meyer F. Successful transgastric pancreaticography and endoscopic ultrasound-guided drainage of a disconnected pancreatic tail syndrome. *Therap Adv Gastroenterol* 2011; **4**: 213-218 [PMID: 21765865 DOI: 10.1177/1756283X10394232]
 - 51 **Arvanitakis M**, Delhaye M, Bali MA, Matos C, Le Moine O, Devière J. Endoscopic treatment of external pancreatic fistulas: when draining the main pancreatic duct is not enough. *Am J Gastroenterol* 2007; **102**: 516-524 [PMID: 17335445 DOI: 10.1111/j.1572-0241.2006.01014.x]
 - 52 **Basha J**, Lakhtakia S, Nabi Z, Pal P, Chavan R, Talukdar R, Ramchandani M, Gupta R, Kalapala R, Venkat Rao G, Reddy DN. Impact of disconnected pancreatic duct on recurrence of fluid collections and new-onset diabetes: do we finally have an answer? *Gut* 2020 [PMID: 32816965 DOI: 10.1136/gutjnl-2020-321773]
 - 53 **Bang JY**, Wilcox CM, Trevino J, Ramesh J, Peter S, Hasan M, Hawes RH, Varadarajulu S. Factors impacting treatment outcomes in the endoscopic management of walled-off pancreatic necrosis. *J Gastroenterol Hepatol* 2013; **28**: 1725-1732 [PMID: 23829423 DOI: 10.1111/jgh.12328]



Published by **Baishideng Publishing Group Inc**
7041 Koll Center Parkway, Suite 160, Pleasanton, CA 94566, USA

Telephone: +1-925-3991568

E-mail: bpgoffice@wjgnet.com

Help Desk: <https://www.f6publishing.com/helpdesk>

<https://www.wjgnet.com>

