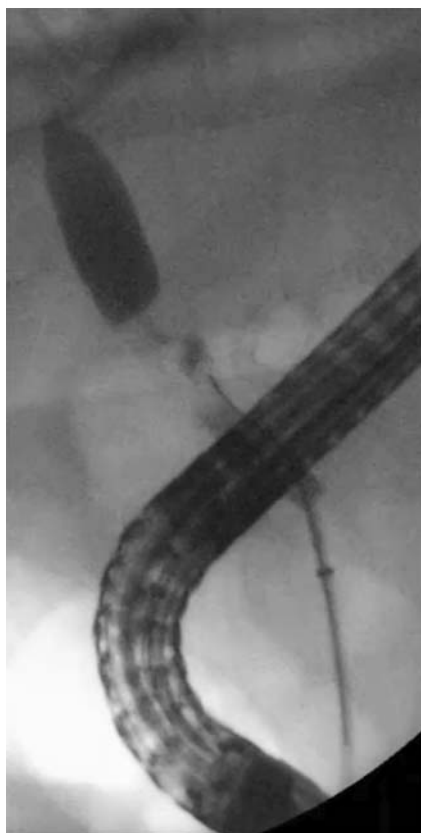

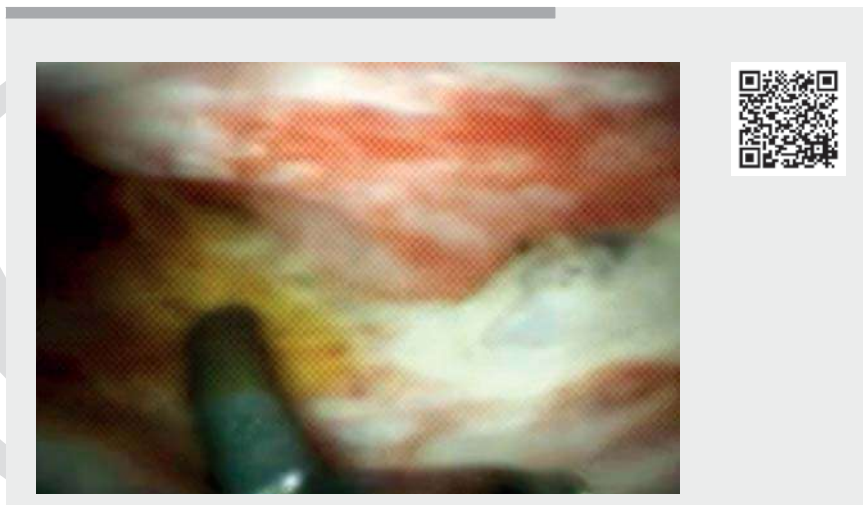
Role of cholangioscopy and therapeutic options in complex anastomotic strictures after liver transplantation



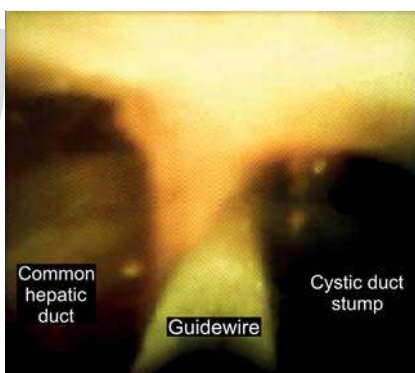
► **Fig. 1** Complex anastomotic stricture.

Biliary strictures are among the most frequent complications following liver transplantation [1,2]. Endoscopic treatment remains challenging; however, cholangioscopy may be an underutilized technique to improve outcomes for complex cases.

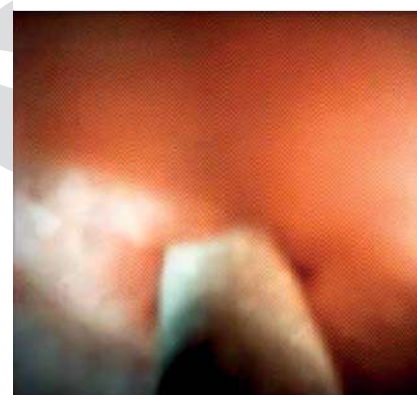We report a case of a 35-year-old gentleman who underwent orthotopic liver transplantation for fulminant hepatitis B. He subsequently developed a hepatic artery thrombosis 9 months after the transplantation and was treated at that time with an endovascular stent. An increase in liver biochemical tests was detected 3 months later. Magnetic resonance cholangiopancreatography (MRCP) identified a biliary anastomotic stricture. Endoscopic retrograde cholangiopancreatog-



► **Video 1** Role of cholangioscopy and therapeutic options in complex anastomotic strictures after liver transplantation.



► **Fig. 2** Cholangioscopy reveals preferential guidewire passage into the cystic duct stump.



► **Fig. 3** Cholangioscopy-assisted guidewire passage through the tight stricture.

raphy (ERCP) (► **Video 1**) revealed a complex anastomotic stricture (► **Fig. 1**) that could not be traversed owing to narrow diameter, axis angulation, and preferential guidewire passage into the cystic duct stump (► **Fig. 2**). Using the cholangioscope, it was possible to place the 0.025-in guidewire through the tight stricture (► **Fig. 3**) and dilate with an 8-mm balloon. Cholangioscopy revealed a pale mucosa in the stenotic

area with fibrosis, debris, and suture material. A 10 Fr×10cm plastic stent was placed.

On routine follow-up ERCP, the stricture was again dilated, and three 8.5Fr×10cm plastic stents were placed. Due to the tortuous, complex stricture with significant axis deviation, a 10mm×6cm fully covered self-expandable metal stent (SEMS) was placed at the subsequent ERCP.


At 4 months after SEMS placement, an additional ERCP was performed for follow-up. During the procedure, the SEMS was not identified with stent migration. Given the fluoroscopic findings, patient's clinical status, and normalization of laboratory tests, the decision was made to not replace the stent. The patient remained asymptomatic with no need for further procedures at 2-year follow-up. Cholangioscopy may serve as an effective tool for the endoscopic treatment of complex biliary strictures after liver transplantation [3]. In this case, the patient was able to avoid percutaneous biliary drainage and improve his quality of life. For patients with complex strictures associated with axis deviation, SEMS may be a better option compared to plastic stents [4, 5].

Endoscopy_UCTN_Code_TTT_1AR_2AG

Competing interests

Eduardo Guimarães Hourneaux de Moura is a consultant for Boston Scientific and Olympus.

The authors

Mateus Pereira Funari¹  Bruno Salomão Hirsch¹  Tomazo Prince Franzini¹  Diogo Turiani Hourneaux de Moura¹  Antonio Afonso Miranda Neto¹, Thomas R. McCarty², Eduardo Guimarães Hourneaux de Moura¹ 

¹ Gastrointestinal Endoscopy Unit, Department of Gastroenterology, Hospital das Clínicas da Faculdade de Medicina da Universidade de São Paulo, Brazil

² Division of Gastroenterology, Hepatology and Endoscopy, Harvard Medical School, Brigham and Women's Hospital, Boston, MA, USA

Corresponding author

Bruno Salomão Hirsch, MD

Hospital das Clínicas da Faculdade de Medicina da Universidade de São Paulo, Av. Dr Enéas de Carvalho Aguiar, 225, 6º Andar, Bloco 3, Cerqueira César, São Paulo, SP, 05403-010, Brazil
Fax: +55112661-6467
brunosalomah@hotmail.com

References

- [1] Larghi A, Tringali A, Rimbaş M et al. Endoscopic management of benign biliary strictures after liver transplantation. *Liver Transpl* 2019; 25: 323–335
- [2] Bokemeyer A, Gross D, Brückner M et al. Digital single-operator cholangioscopy: a useful tool for selective guidewire placements across complex biliary strictures. *Surg Endosc* 2019; 33: 731–737
- [3] de Oliveira PVAG, de Moura DTH, Ribeiro IB et al. Efficacy of digital single-operator cholangioscopy in the visual interpretation of indeterminate biliary strictures: a systematic review and meta-analysis. *Surg Endosc* 2020; 34: 3321–3329
- [4] Poley JW, Ponchon T, Puespoek A et al. Benign Biliary Stenoses Working Group. Fully covered self-expanding metal stents for benign biliary stricture after orthotopic liver transplant: 5-year outcomes. *Gastrointest Endosc* 2020; 92: 1216–1224
- [5] Visconti TAC, Bernardo WM, Moura DTH et al. Metallic vs plastic stents to treat biliary stricture after liver transplantation: a systematic review and meta-analysis based on randomized trials. *Endosc Int Open* 2018; 6: E914–E923

Bibliography

Endoscopy

DOI 10.1055/a-1704-7503

ISSN 0013-726X

published online 2021

© 2021. Thieme. All rights reserved.

Georg Thieme Verlag KG, Rüdigerstraße 14,

70469 Stuttgart, Germany

ENDOSCOPY E-VIDEOS

<https://eref.thieme.de/e-videos>



Endoscopy E-Videos is a free access online section, reporting on interesting cases and new

techniques in gastroenterological endoscopy. All papers include a high quality video and all contributions are freely accessible online.

This section has its own submission website at

<https://mc.manuscriptcentral.com/e-videos>