

Peroral endoscopic pyloromyotomy for gastroparesis: a systematic review and meta-analysis



Authors

Karime Lucas Uemura, Dalton Chaves, Wanderley M. Bernardo, Ricardo Sato Uemura, Diogo Turiani Hourneaux de Moura, Eduardo Guimarães Hourneaux de Moura

Institution

Gastrointestinal Endoscopy Unit, Hospital das Clínicas da Faculdade de Medicina da Universidade de São Paulo, São Paulo, Brazil

submitted 23.10.2019

accepted after revision 6.1.2020

Bibliography

DOI <https://doi.org/10.1055/a-1119-6616> |
Endoscopy International Open 2020; 08: E911–E923
© Georg Thieme Verlag KG Stuttgart · New York
eISSN 2196-9736

Corresponding author

Karime Lucas Uemura, Universidade de Sao Paulo Hospital das Clinicas – Gastrointestinal Endoscopy Unit, Av. Dr. Enéas Carvalho de Aguiar, 255 – Cerqueira César Sao Paulo, Sao Paulo 05403-000, Brazil
Fax: +551130697579
karime_lucas@hotmail.com

ABSTRACT

Background and aim Gastric peroral endoscopic pyloromyotomy (G-POEM) is a new therapeutic option for refractory gastroparesis (GP). A systematic review and meta-analysis was conducted to assess the effectiveness of G-POEM in

refractory GP. For the quality of evidence, we used the Grading of Recommendations Assessment, Development and Evaluation (GRADE) criteria.

Methods We performed a literature search using MEDLINE, Embase, Cochrane library, LILACS and the Science citation index for studies related to G-POEM from the inception of its technique through January 2019. We selected studies that analyzed the gastroparesis cardinal symptom index (GCSI) and 4-hour solid-phase gastric emptying scintigraphy (GES) before and after the procedure to verify the efficacy of G-POEM, the main outcome measured. An analysis was performed using RevMan 5.3.

Results Ten studies comprising 281 patients were included in this systematic review. The pooled mean difference in GCSI following the procedure was 1.76 (95% CI: [1.43, 2.08], $I^2=72\%$). We also performed GCSI subgroup analysis by follow-up duration that showed a pooled mean difference of 1.84 (95% CI: [1.57, 2.12], $I^2=71\%$). The pooled mean difference in GES after the procedure was 26.28 (95% CI: [19.74, 32.83], $I^2=87\%$), corresponding to a significant drop in percentage values of the gastric retention 4-hour scintigraphy.

Conclusion This meta-analysis demonstrates that G-POEM is effective and shows promising outcomes in the clinical response and gastric emptying scintigraphy for gastroparesis. Therefore, it should be considered in the management of refractory gastroparesis.

Introduction

Gastroparesis (GP) is a difficult-to-treat syndrome in which the diagnosis is suspected because of a constellation of clinical symptoms and is further confirmed based on normal upper endoscopy ruling out any structural obstruction and a 4-hour gastric emptying study proving impaired gastric emptying [1].

Multiple conditions have been associated with gastroparesis, and most etiologies are postsurgically related, diabetic, or idiopathic [2]. Postinfectious, infiltrative and neurological disorders such as amyloidosis and Parkinsonism are also associated [3].

The pathogenesis of delayed gastric emptying is associated with fundus abnormalities, antrum and antroduodenal discoordination, pyloric dysfunction, and abnormal small bowel motility [4]. The pathogenesis of gastroparesis comprises two main components: altered gastric motility and increased pyloric pressure [5].

Gastroparesis treatment involves clinical, surgical and endoscopic interventions.

Surgical and endoscopic interventions may be options for patients with medical refractory gastroparesis [6].

Gastroparesis treatment involves clinical, surgical and endoscopic interventions, and it usually begins with diet modifica-

tion (low-fat, low-fiber diet) and medications such as antiemetics and prokinetic agents that accelerate gastric emptying and relief symptoms [2, 3]. Surgical and endoscopic interventions may be options for patients with medical refractory gastroparesis [6]. Endoscopic treatment options are pyloric botulinum toxin injection, which did not confirm its efficacy in two recent randomized studies [7, 8], dilation, transpyloric stent placement and gastric peroral endoscopic myotomy (G-POEM) [9–11], which is a novel and promising technique that has been introduced recently. From the first use of G-POEM experimentally in 2012 by Kawai et al. and Chaves et al. [12, 13] to the first G-POEM performed in humans in 2013 by Khashab et al., followed by Chaves et al. [14, 15] this technique has risen in popularity.

Due to its minimally invasive nature, promising outcomes and few adverse events, G-POEM or peroral endoscopic pyloromyotomy (POP) has become a very attractive therapy for refractory gastroparesis with several observational studies and case reports being described. However, to date, no long-term study and no consensus on the efficacy and safety of this technique exists. Thus, we aimed to perform a systematic review data on G-POEM and meta-analysis assessing the efficacy of this procedure.

Methods

Protocol and registration

The systematic review was carried out in accordance with the Preferred Reporting Items for Systematic Reviews and Meta-Analyses (PRISMA) guidelines [16] and Meta-Analysis of Observational Studies in Epidemiology (MOOSE) guidelines It was registered in the PROSPERO international database (www.crd.york.ac.uk/prospero/) under the number CRD42019142502.

Eligibility criteria

- Type of study: case series, published abstracts and cohort studies.
- Type of participant: patients older than 18 years undergoing G-POEM with refractory gastroparesis
- Type of intervention: gastric peroral endoscopic pyloromyotomy
- Type of outcome measure: the main outcome measure was G-POEM efficacy, defined by improvement in the gastric cardinal symptom index (GCSI) and gastric emptying scintigraphy (GES).

Information sources

A systematic literature search was performed in MEDLINE, Embase, Cochrane Central Register of Controlled Trials (CENTRAL) and LILACS through January 2019.

Search and study selection

The following search terms were used in various combinations: gastroparesis, gastric emptying, gastric empty delay, gastric stasis, gastric peroral endoscopic pyloromyotomy (G-POEM), peroral endoscopic pyloromyotomy (POP), endoscopic, endoscopy, surgery, pyloroplasty and pyloromyotomy. Two authors independently searched and extracted the data in a standard-

ized manner. Any differences between the reviewers were resolved by consensus.

The articles were screened for the presence of the following inclusion criteria: adult patients with a diagnosis of gastroparesis. Study designs as case reports, cohort and published abstracts were included. Articles in English and Spanish language were included. Experimental studies in animal models and reviews were excluded. Articles were selected for full-text review based on their title and abstract. A manual search through the bibliographies of the retrieved publications was conducted to increase the yield of potentially relevant articles. Additionally, the authors were contacted to obtain unpublished data from their studies, whenever necessary.

In cases where multiple publications were available with an increasing number of patients or a longer follow up for the same group, only data from the most recent article was used for statistical analysis. We only selected studies with GCSI and GES with the mean difference and standard deviation data calculated.

We used a flow diagram to summarize the study selection process.

Data collection process

Data collection was performed by two reviewers (K.L.U. and D.C.) independently. Disagreements between reviewers were discussed with a third reviewer (W.M.B.), and agreement was reached by consensus. The studies had to analyze GCSI and GES before and after G-POEM, in patients with gastroparesis.

We extracted the following variables: name and year of study; design of study; age; male/female distribution; total number of patients included; number of patients who underwent G-POEM; technical success, clinical success, adverse events, procedure time, myotomy length and length of hospital stay.

Risk of bias and quality of studies

Publication bias was assessed where necessary by funnel plots and the Egger test of asymmetry. Quality assessment was performed by two authors independently using the Joanna Briggs Index for case series. The quality of evidence was assessed using the Grading of Recommendations Assessment, Development and Evaluation (GRADE) criteria with the GRADEpro Guideline Development Tool software (McMaster University, 2015; Evidence Prime, Inc., Ontario, Canada) [18].

Data synthesis and statistical analysis

We evaluated the following outcomes in this meta-analysis: (i) gastroparesis cardinal symptom index (GCSI) before and after G-POEM and (ii) gastric emptying scintigraphy at 4 hours (GES) before and after G-POEM. True heterogeneity was presumed and the random effects model was applied in case of persistent high heterogeneity. Heterogeneity was evaluated using Inconsistency (I^2) statistics and the Cochran Q test, in which $P < 0.05$ for the Cochran Q test indicated the presence of heterogeneity. The I^2 values $> 50\%$ were consistent with significant heterogeneity. Tests of significance comparing pre- and post-procedure outcomes of interest were performed using two sample t tests

or analysis of variance (ANOVA) for continuous variables and chi-square or Fisher exact test for categorical variables. All statistical analyses were conducted using RevMan software (Review Manager Version 5.3; The Nordic Cochrane Centre, Copenhagen, Denmark) and Comprehensive Meta-Analysis (CMA) software (version 3.0; Biostat, Englewood, New Jersey, United States).

Results

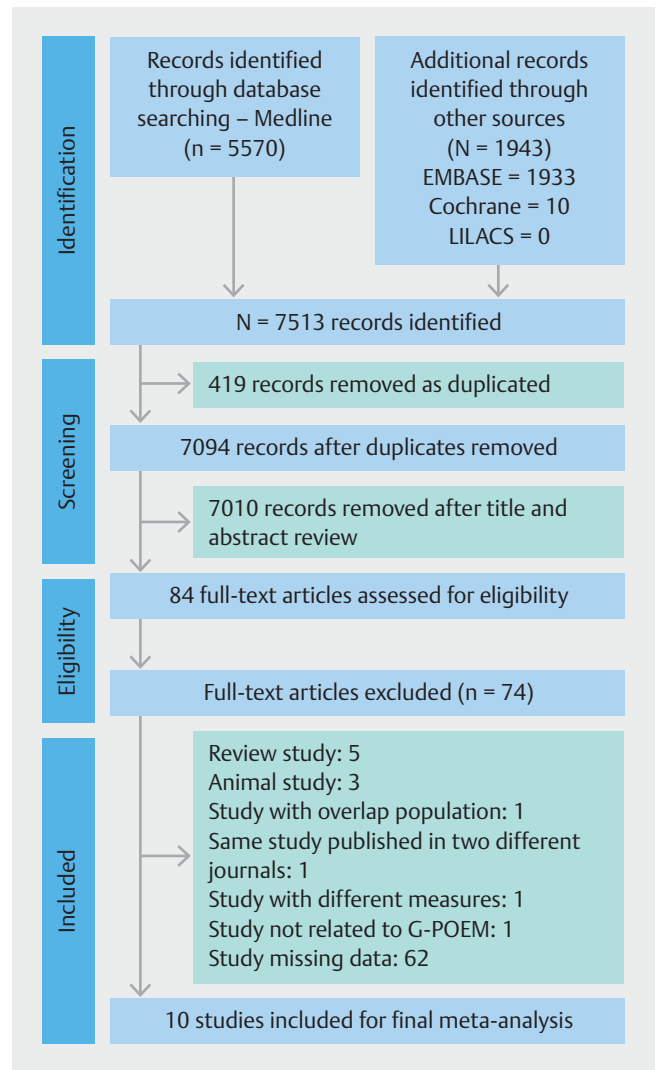
Study selection

The search strategy identified 7,513 publications, of which 419 were removed as duplicate publications and 7,010 were excluded based on title and abstract review. A total of 84 articles underwent full-text review, of which 76 studies were further excluded for various reasons: five studies were review articles, three were animal studies, one study had an overlap population, one study was published in two different journals, one was not related to G-POEM, and one study presented different GCSI data. We only selected studies with calculated standard deviation values (SD); thus, we had to exclude 62 additional studies missing GCSI and/or GES data. Therefore, 10 studies were included in this meta-analysis. An adapted PRISMA flow diagram illustrates the study selection process (► Fig. 1).

Study characteristics and quality assessment

Among the 10 studies included in this meta-analysis, four were prospective [19–22], including two published abstracts [20, 21], and 6 were retrospective [1, 23–27], including also another abstract [27], which we chose instead of the published article from the same group, because it is more recent and has a larger number of patients [28]. In total, 281 patients were included in this meta-analysis. We excluded 3 patients from the Xue et al. [26] study in which the pyloric ring was not identified during routine G-POEM. A summary of the characteristics of the included studies is shown in ► Table 1. Landrenau et al. [1] were the only authors who compared G-POEM to laparoscopic pyloroplasty; thus, we did not analyze the laparoscopic data. Mekaroonkamol et al. [23] aimed to identify predictive factors of the clinical response after G-POEM and compared outcomes between diabetes gastroparesis and non-diabetes gastroparesis (NDG). Xue et al. [26] performed fluoroscopy-guided G-POEM to direct the orientation of the submucosal tunnel, to facilitate the location of the pyloric muscle ring and shorten the procedure time, while Malik et al. and Jacques et al. [22, 24] used EndoFLIP to determine whether pyloric sphincter characteristics existed that could predict a successful procedure. The remaining authors performed routine G-POEM.

Using the Joanna Briggs Institute (JBI) Critical Appraisal Checklist for Case Series quality assessment, all 10 studies did not clearly report the demographics of the participants. Five studies did not report clear information about the participants [20–23, 27] and two were unclear [25, 26]. The Hustak et al. [20] study was the only one that did not report clear information about the site/clinic demographic information. Quality assessment is shown in ► Table 2.



► Fig. 1 Search strategy and study selection flowchart.

Meta-analysis

GCSI

Ten studies were included with 281 patients to evaluate the general GCSI before and after the procedure, and the longest follow-up values from each study were included in this analysis. The pooled mean difference in GCSI following the procedure with a 95% confidence interval was 1.76 [1.43, 2.08] by the Cochran Q test ($P=0.0002$, $I^2=72\%$) (► Fig. 2). All the studies reported a decrease in the values of GCSI after G-POEM, and we used the longest follow up to calculate this. However, we found one study with publication bias, from Malik et al. [24], which was presented as an outlier during the general analysis. The I^2 values dropped from 72% to 50% after excluding this study as shown in ► Fig. 3 and ► Fig. 4. There were different baseline GCSI values among the included studies, with different disease severities but although statistically significant ($P<0.0000001$), these differences are already expected in this type of meta-analysis.

▶ Table 1 Characteristics of included studies.

Study	Study design	Patients No (n)	Age	Gender (F:M)	Definition of gastroparesis	Etiology			Procedure duration (minutes)	Myotomy length (cm)	Hospital stay (days)	Clinical success (%/month)	Follow-up (months)	
						Dia-betes	Idio-pathic	Post-surgical						Others
Rodriguez J. et al, 2018	Prospective January 2016 to October 2017	100	45 ± 14.6	85:15	Patients with ongoing symptoms after at least 6 mo of medical therapy	21	56	19	4	33.8 ± 21.6	N/A	1.3 ± 1.05	N/A	3
Landreneau et al, 2018	Retrospective October 2014 to September 2017	30	44.1 ± 13.5	23:7	Patients who fail to achieve durable response or are unable to tolerate medical therapies	5	19	6	0	33.9 ± 18.8	N/A	1.4 ± 1.0	N/A	3
Malik Z. et al, 2018	Retrospective October 2015 to October 2016	13	45.7 ± 10.3	7:6	N/A	1	4	8	0	64.4 ± 17.1	3.5 ± 0.8	2.5 ± 1.4	73% (3mo)	3
Gonzalez J.M. et al, 2017	Retrospective January 2014 to April 2016	29	52.8 ± 17.7	19:10	Symptoms > 6 months, with failure of all prokinetic, and a mean GCSI > 1.5	7	15	5	2	47 ± 22	N/A	N/A	79% (3mo) 69% (6mo)	10 ± 6.4
Xue H.B. et al, 2017	Retrospective May 2015 to July 2016	11/14	44 ± 15	8:6	Patients who have failed medical therapy and other interventional therapies (endoscopic Botox injection, gastric electrical stimulation), and patients who have to rely on jejunum tube feeding or total parenteral nutrition (TPN)	6	6	1	1	42.25 ± 12.96	3	2.46 ± 0.7	N/A	2
Mekaroonkamol P. et al, 2019	Retrospective June 2015 to September 2017	40	47.7 ± 15.5	35:5	Patients who failed to respond or could not tolerate to dietary modification, prokinetic or electrical stimulator	15	18	5	2	56.2 ± 24.1	N/A	N/A	80% (1mo) 71.9% (6mo)	18
Hustak R. et al, 2018	Prospective Since November 2015	7	N/A	N/A	N/A	2	1	4	0	70 min (63–106)	N/A	N/A	85% (3mo and 6mo)	24
Dacha S. et al, 2017	Retrospective June 2015 to October 2016	22	44.9 ± 16.3	19:3	Patients who failed to respond to dietary modification, prokinetic or electrical stimulator	13	7	1	1	44.9 ± 15.8	2.88 ± 0.3	2.5 ± 1.1 dias	77.3%	6.6 ± 4.5
Hernandez-Mondragon O.V. et al, 2017	Prospective December 2016 to April 2017	9	42.4 ± 8.5	6:3	Unresponsive medical treatment patients that have a positive GCSI score combined with > 10 % of retention at 4h-GES	3	2	4	0	61.4 ± 7.8	N/A	N/A	77% (3mo)	3
Jacques J. et al, 2019	Prospective April 2016 to June 2017	20	N/A	N/A	Persistent symptoms and reduced quality of life despite 6 months of continuous treatment	10	4	1	5	56 min	N/A	3.75	90% (3mo)	3

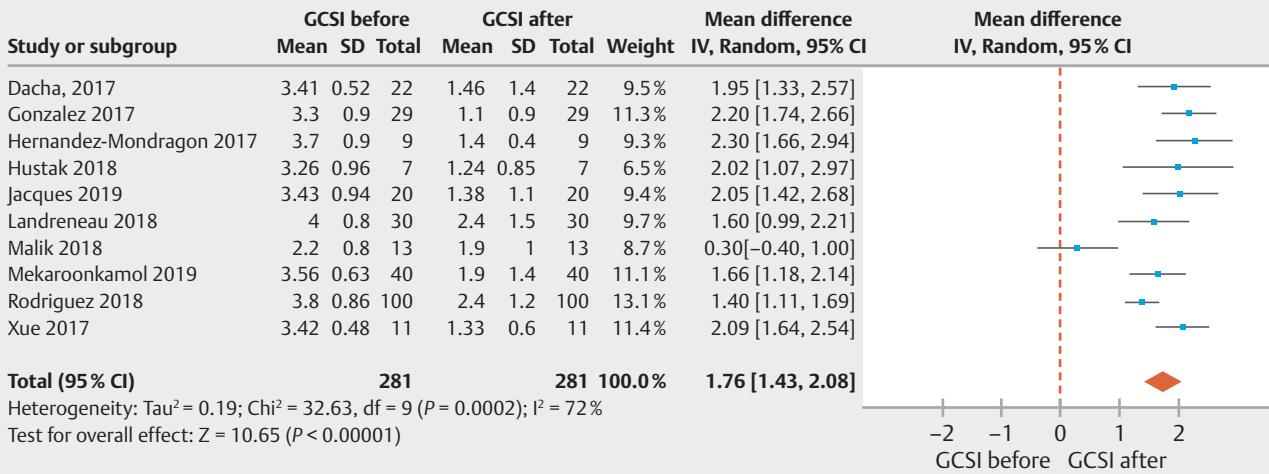
► **Table 2** Quality assessment studies for case series.

Joanna Briggs Institute – JBI	Rodriguez et al, 2018	Landreneau et al, 2018	Malik et al, 2018	Gonzalez et al, 2017	Xue et al, 2017	Mekaroonkamol et al, 2019	Hustak et al, 2018	Dacha et al, 2017	Jacques J. et al, 2019	Hernandez-Mondragon O.V. et al, 2017
Were there clear criteria for inclusion in the case series?	Y	Y	Y	Y	Y	Y	Y	Y	Y	Y
Was the condition measured in a standard, reliable way for all participants included in the case series?	Y	Y	Y	Y	Y	Y	Y	Y	Y	Y
Were valid methods used for identification of the condition for all participants included in the case series?	Y	Y	Y	Y	Y	Y	Y	Y	Y	Y
Did the case series have consecutive inclusion of participants?	Y	Y	Y	Y	Y	Y	Y	Y	Y	Y
Did the case series have complete inclusion of participants?	Y	Y	Y	Y	Y	Y	Y	Y	Y	Y
Was there clear reporting of the demographics of the participants in the study?	N	N	N	N	N	N	N	N	N	N
Was there clear reporting of clinical information of the participants?	Y	Y	Y	U	U	N	N	N	N	N
Were the outcomes or follow up results of cases clearly reported?	Y	Y	Y	Y	Y	Y	Y	Y	Y	Y
Was there clear reporting of the presenting site(s)/clinic(s) demographic information?	Y	Y	Y	Y	Y	Y	N	Y	Y	Y
Was statistical analysis appropriate?	Y	Y	Y	Y	Y	Y	Y	Y	Y	Y
Overall appraisal:	Include	Include	Include	Include	Include	Include	Include	Include	Include	Include

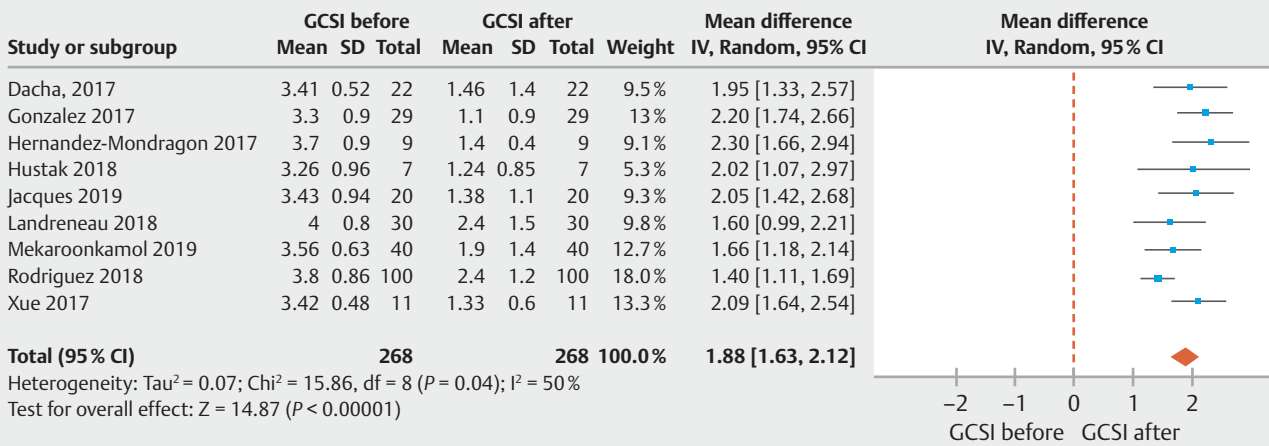
GCSI subgroup

We also analyzed GCSI 3, 6, 12 and 18 months following the procedure. The Xue et al. [20] study was not included in this subgroup analysis because the results were described at the 1-month follow up. Gonzalez et al. [25], Hustak et al. [20], Landreneau et al. [1], Malik et al. [24], Jacques et al. [22], Hernandez Mondragon et al. [21] and Rodriguez et al. [19] reported the mean difference between GCSI before and after 3 months of G-POEM with a 95% confidence interval as 1.76 [1.26–2.25] by the Cochran Q test ($P < 0.0001$, $I^2 = 81\%$). Although the hetero-

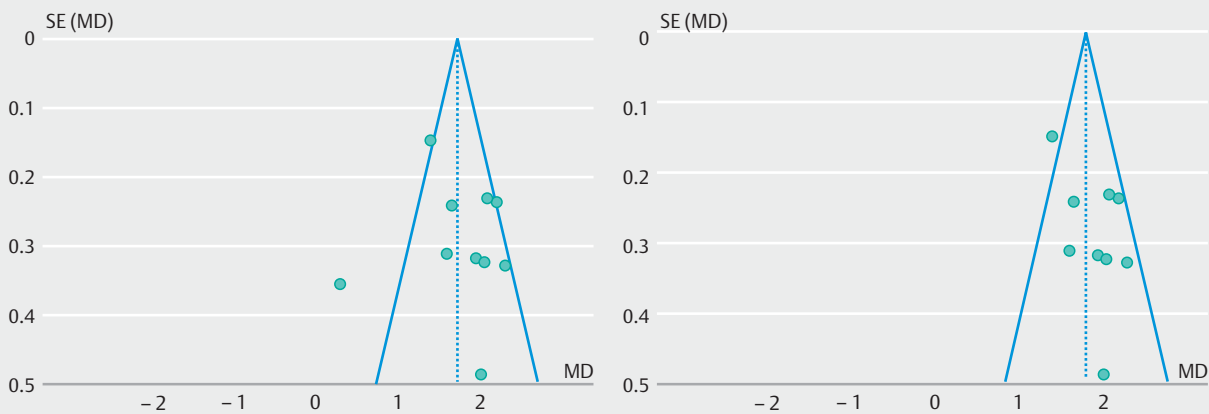
geneity was high, all the studies showed improvement in the GCSI score after the procedure. Four studies completed 6 months of follow up [20, 27], two studies completed 12 months [20, 27], and one study 18 months [23] following the procedure. These studies showed a decrease in the values of GCSI after G-POEM, and the overall mean difference for the GCSI subgroup was 1.84 [1.57–2.12] with a 95% confidence interval by the Cochrane Q test ($P < 0.0001$; $I^2 = 71\%$) (► Fig. 5). Hustak et al. [20] reported that one woman completed 24 months of follow up, although their complete data are missing.



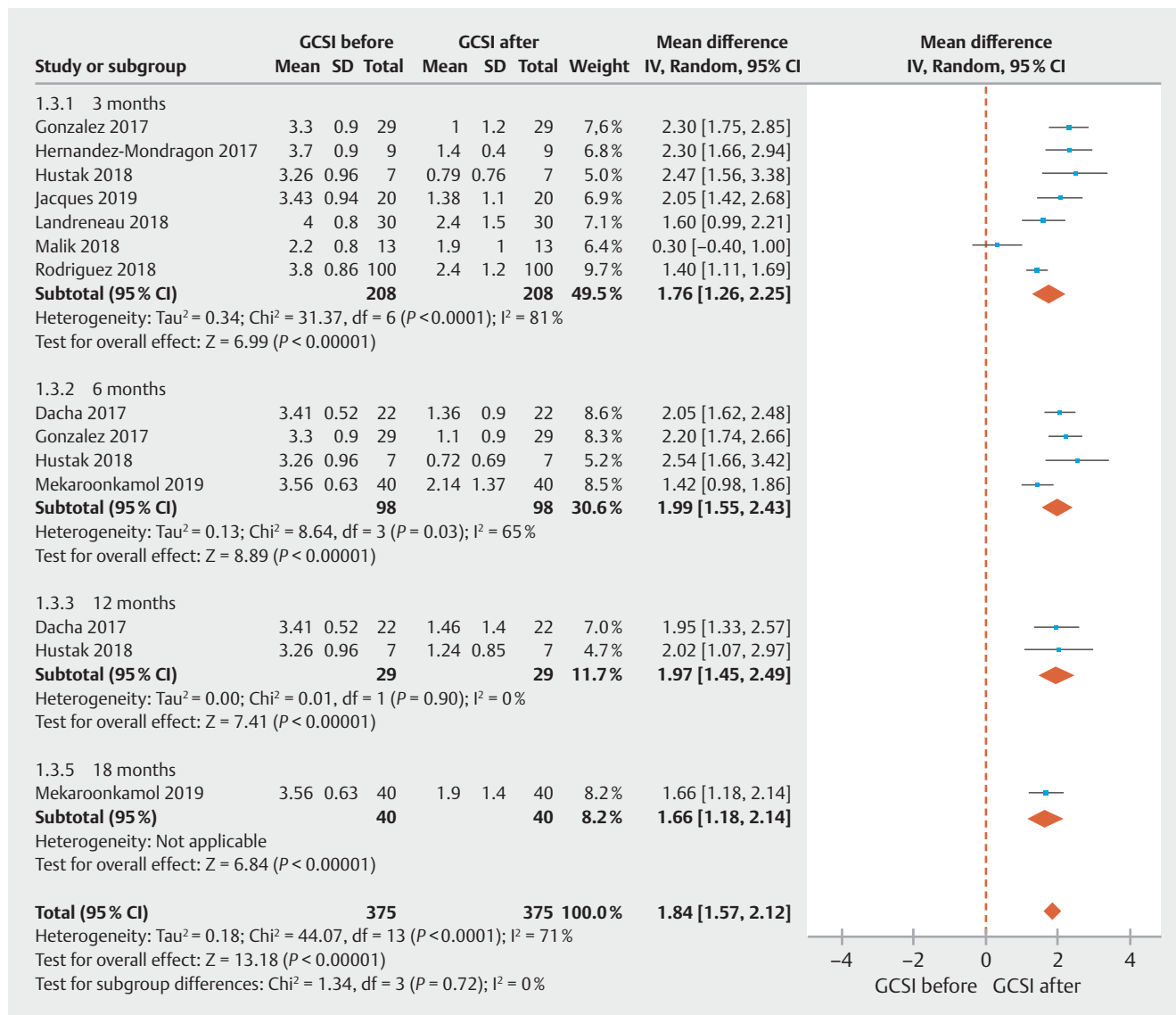
► Fig. 2 Forest plot to compare GCSI before and after G-POEM.



► Fig. 3 Forest plot to compare GCSI before and after G-POEM without the outlier.



► Fig. 4 Funnel plot to show the outlier study in GCSI analysis.



► Fig. 5 Forest plot to compare GCSI subgroup before and after G-POEM.

GES

For GES, all ten studies were included with 252 patients. The patients had preoperative GES, and the GES control was performed 2 to 3 months after the procedure. There was a significant decrease in the percentage of the gastric retention 4-hour scintigraphy after the procedure, and the mean difference was 26.28 [19.74–32.83] with the 95% confidence interval by the Cochrane Q test ($P < 0.00001$; $I^2 = 87\%$). Therefore, the heterogeneity was as high as that encountered in the GCSI results (► Fig. 6).

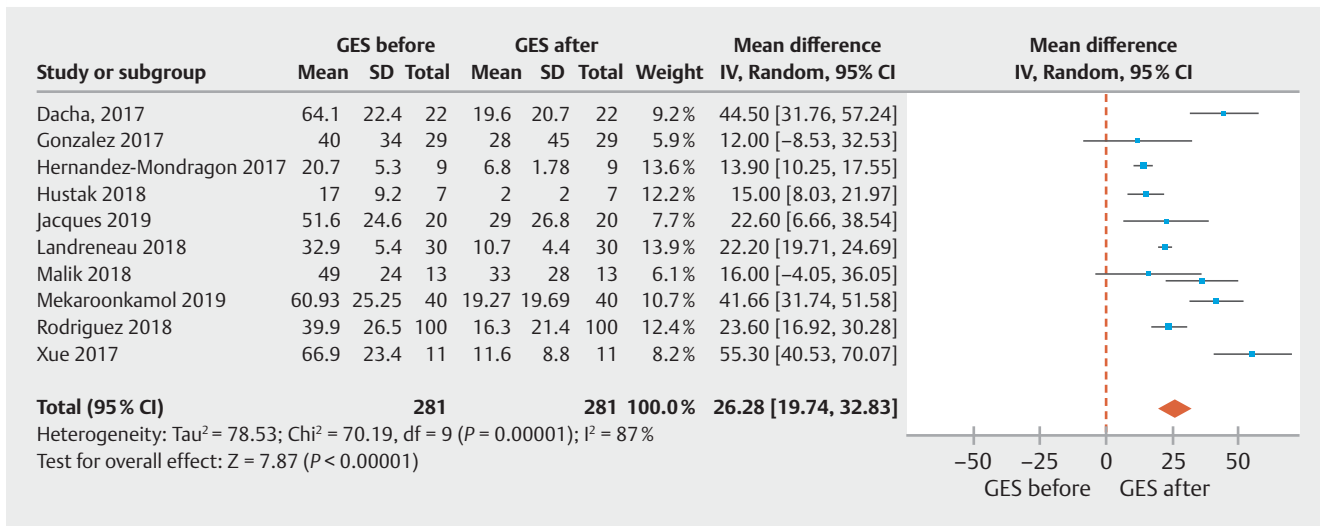
According to the GRADE criteria for the quality of evidence, the evidence for our GCSI outcomes generated low certainty and for the GCSI subgroup and GES, very low certainty, as shown in ► Table 3.

Discussion

Summary of evidence

To our knowledge, this is the first systematic review and meta-analysis including published papers and abstracts studies that compared GCSI and GES values pre- and post G-POEM in cases of refractory gastroparesis, based on data with mean difference and calculated standard deviation data of each study. Our strict methodology, which included critical appraisal of biases, quality of evidence assessment, and a report prepared in accordance with the PRISMA guidelines [16], underscores the strength of our findings. G-POEM seems to be a very good option in the arsenal treatment for refractory gastroparesis, with a rate of 100% technical success and 71% clinical success.

First-line therapies on the management of GP are diet modification (low fat, low fiber diet) and medications such as antiemetics and prokinetic agents that accelerate gastric emptying



► **Fig. 6** Forest plot to compare GES before and after G-POEM.

► **Table 3** Quality (certainty) of evidence of the studies selected, as determined by the GRADE criteria.

Certainty assessment							No. of patients		Effect		Certainty	Importance
No. of studies	Study design	Risk of bias	Inconsistency	Indirectness	Imprecision	Other considerations	GCSI and GES before G-POEM	After G-POEM	Relative (95% CI)	Absolute (95% CI)		
GCSI (follow up: range 3 months to 18 months; Scale from: 0 to 5)												
10	Observational studies	Not serious	Not serious	Not serious	Not serious	None	281	281	–	MD 1.62 higher (1.45 higher to 1.8 higher)	⊕⊕○○ Low	Important
GES												
10	Observational studies	Not serious	Very serious ¹	Not serious	Not serious	None	281	281	–	MD 26.62 higher (19.7 higher to 33.55 higher)	⊕○○○ Very low	Important
GCSI subgroup												
9	Observational studies	Not serious	Serious ²	Not serious	Not serious	Publication bias strongly suspected	375	375	–	MD 1.79 higher (1.49 higher to 2.09 higher)	⊕○○○ Very low	Important

CI, confidence interval; MD, mean difference; GCSI, gastroparesis cardinal symptom index; GES, gastric emptying scintigraphy; G-POEM, gastric peroral endoscopic pyloromyotomy.

¹ Heterogeneity above 75%

² Heterogeneity between 50% and 75%

and relief symptoms. Metoclopramide and domperidone, a D2 dopamine receptor antagonist, are the most widely used drugs, but only metoclopramide is currently approved by the Food and Drug Administration (FDA) in the United States. This treatment has limited efficacy and carries a black-box warning for tardive dyskinesia [29, 30]. This makes management more challenging, and patients frequently present with severe symptoms due to either progression of the disease or medications losing efficacy over time, turning the disease refractory to medical treatment [31].

Surgery may be next step for treatment of refractory gastroparesis. The surgery options include implantation of gastric stimulators, Roux-en-Y gastric bypass, subtotal gastrectomy, gastrostomy, jejunostomy and pyloric interventions such as pyloromyotomy and pyloroplasty [6, 32]. However, gastric electrical stimulation has often been considered first line in the treatment of medically refractory patients with the best level of evidence [33].

Gastric electrical stimulation is a surgically implanted treatment option to treat gastroparesis resistant to medical therapy

► **Table 4** Excluded studies.

Study	Study Design	Patients No (n)	Reason for exclusion
Jiaxin Xu et al, 2018	Retrospective Single center – China	16	GES 4 h missing data
Kahaleh M. Et al, 2018	Case series Multicenter – USA/France	33	Missing SD data
Khashab M. et al, 2017	Retrospective Multicenter – USA/Asia/South America	30	GCSI missing data / Invalidated symptoms questionnaire
Allemang M.T. et al, 2017	Retrospective Single center – USA	57	GES missing data
Shlomovitz E. et al, 2015	Retrospective Single center – USA	7	GCSI missing data / Invalidated symptoms questionnaire

[32]. This therapy seems to significantly decrease gastrointestinal symptoms and improve the quality of life in patients with severe gastroparesis [34]. However, complications occur in 5% to 20% of patients, such as infections, migration and erosion of the stimulating device, gastric perforation, abdominal pain, dislodgment, stomach wall perforation and intestinal obstruction [33, 35]. To minimize complications, simultaneous intraoperative endoscopy is now routinely performed to permit immediate detection of gastric wall perforation, and then electrode repositioning can occur at the same operative moment [34]. Although a role likely exists for gastric stimulation in the treatment of refractory gastroparesis symptoms, there are a substantial number of patients who cannot access the technology or for whom it does not work [36].

Pyloric dysfunction may play a role in a subset of patients with gastroparesis; thus, pyloric interventions have risen in popularity. Surgical techniques have aimed to disrupt pyloric barrier function and facilitate gastric emptying. Botox injections, endoscopic balloon dilatation, pyloroplasty, pyloromyotomy and transpyloric stent placement have all been employed with varying successes [9–11]. Use of botulinum toxin is controversial and has not shown a benefit in randomized trials, although it improves gastric emptying in patients with gastroparesis, this benefit was not superior to placebo and it is no longer recommended by American College of Gastroenterology [7, 8, 37]

Jones et al performed a review of surgical therapy for gastroparesis and demonstrated that gastrectomy, gastric stimulation, gastrostomy, and jejunostomy are not benign interventions and that the true efficacy of these procedures is not known [38]

Laparoscopic pyloroplasty can accelerate gastric emptying and improve symptoms in select patients with a suspicion of pyloric dysfunction and refractory symptoms [11]. Hibbard et al. and Toro et al. described a similar retrospective study of their experience with this procedure in 28 and 50 patients, respectively, reporting symptomatic improvement in 83% and 82%, respectively [36, 39]. Therefore, few complications are described, such as leaks, wound infections and hospital readmission, to control refractory symptoms or for reoperation [1, 11].

Although there seems to be a role for gastric stimulation and laparoscopic pyloroplasty, in the treatment of refractory gastroparesis symptoms, they are invasive techniques with a high

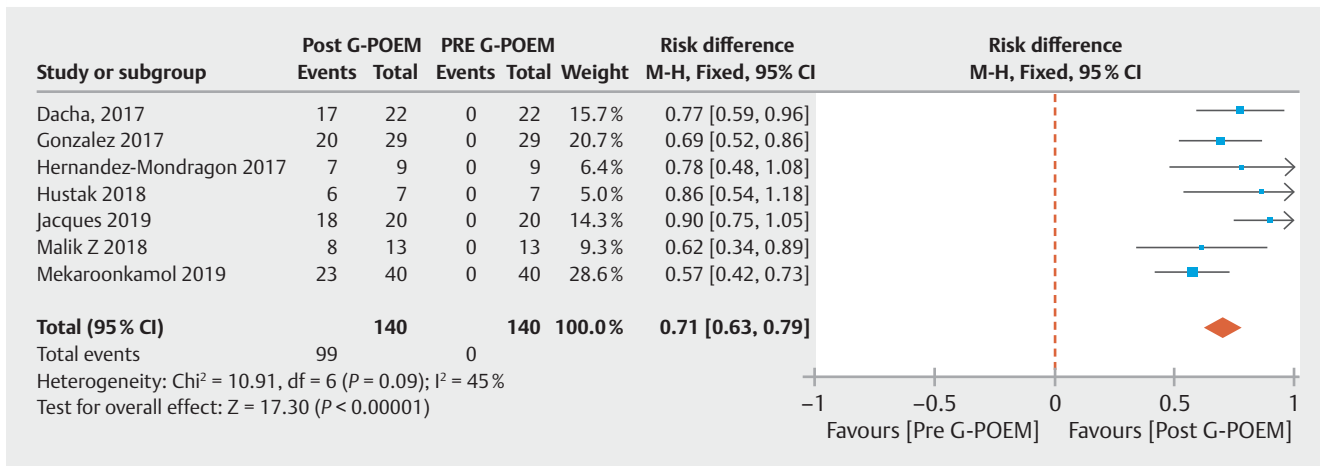
rate of complications and recurrence of patient symptoms, making physicians aim for a novel and less invasive procedure.

Increasingly more studies have been published performing G-POEM for refractory gastroparesis, since it was first performed in 2013. However, no randomized or comparative study exists regarding its safety and efficacy. Nevertheless, all the published studies have reported high rates of clinical success.

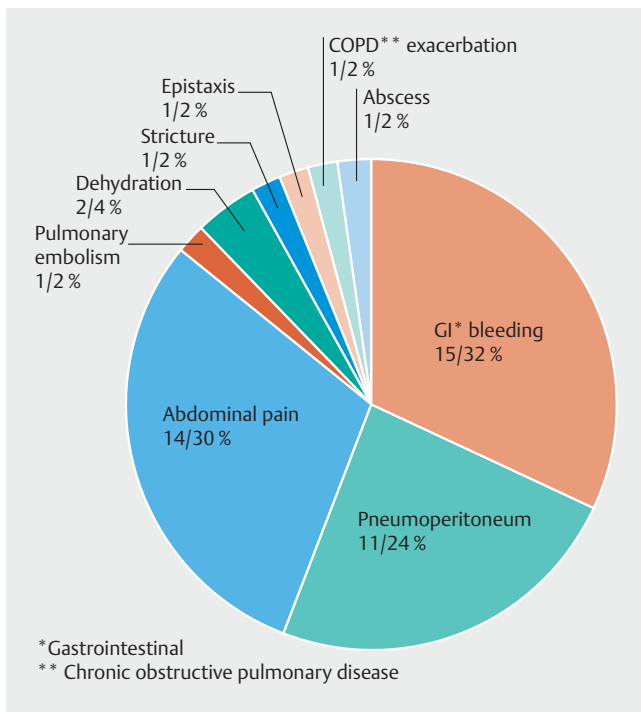
From our search, we found 84 papers on G-POEM worldwide, indicating this technique has been performed increasingly. We could only include 10 studies in this meta-analysis because the studies had to contain all the data for GCSI and GES before and after the procedure with calculated SD values. Many other studies were found, and all of them were related to safety and improvement using either the GES or GCSI scores [31, 40–44]. Khashab et al., for example, unfortunately used an invalidated gastroparesis symptom questionnaire. Thus, the study could not enter this meta-analysis, however, it was the first multicenter study of five centers and included 30 patients, with very consistent results showing a 100% procedural success, an 86% clinical response and a 7% complication rate [31]. Shlomovitz et al. [42] reported the first case series in 2015 but unfortunately, there were missing data and we also couldn't include this study in our analysis. Other excluded studies are shown in ► **Table 4**.

The only study found in the literature that compares G-POEM with laparoscopic pyloroplasty (LP) was described by Landreneau J. et al. and was related to significant improvement in the GES and GCSI scores, with no differences in these outcome measures between the interventions. However, G-POEM appears to be superior to LP because it shows less perioperative morbidity, including the operative time, estimated blood loss, and length of hospital day [1].

The studies included in this meta-analysis demonstrate significant symptom improvement, yielding a pooled mean difference in clinical success of 0.71 (95% CI, [0.63, 0.79] $I^2=45\%$) (► **Fig. 7**). However, the follow-up duration was quite heterogeneous across all studies, varying from 1 to 24 months; therefore, we calculated the clinical success rate with the longest follow-up data available provided in seven studies [20–25, 27]. We included one published abstract in this meta-analysis, from Hustak et al. [20], that has the longest follow-up period, where one woman from a total of seven patients included had finished the 24-month follow up and maintained an excellent outcome (mean GCSI: 0.77). However, unfortunately, we could not in-



► Fig. 7 Forest plot to demonstrate clinical success.



► Fig. 8 Adverse events.

clude this last result in our analysis because it did not have the calculated SD values. All the studies but one showed a significant reduction in the total GCSI after G-POEM [1, 19–23, 25–27]. This lack of significant change in the GCSI values might have been due to its lower GCSI values before the procedure and it may be the reason why Malik et al. [24] is represented as an outlier. However, in this study, it did not seem to have a relevant decrease in GCSI values, most of the patients reported improvement. Another interesting point was that patients with a lower starting GCSI and fewer severe symptoms showed a better response, suggesting that pyloromyotomy should be performed earlier in the disease course rather than in patients who are refractory to other treatments to reach better results

[24]. Only a few studies reported GCSI subscales [1, 22–24]. Jacques et al. and Landreneau et al. [1, 22] showed significant improvement in all GCSI subscales (nausea/vomiting, early satiety and bloating) at 3 months while Mekaroonkamol et al. [23] reported sustained improvement only in the 12-month nausea/vomiting subscale. Malik et al. [24] showed no significant difference between pre and post-GCSI scores.

The endoscopic functional luminal imaging probe (EndoFLIP) is a system that can assess pyloric dysfunction in patients with gastroparesis by measuring the length, pressure, cross sectional area (CSA), and distensibility of the pylorus. Malik et al. [24] showed that the pyloric diameter and CSA were inversely correlated with the symptom severity, such as early satiety and postprandial fullness. However, when they used EndoFLIP measurements pre- and post-G-POEM, only one measurement showed a significant difference when comparing patients who clinically improved with those who did not [24]. The same group showed that, while the average pyloric pressure decreases, the cross-sectional area and pyloric diameter increase significantly after G-POEM. Jacques et al. [22], in a prospective trial, showed that all the subjects benefited from the EndoFLIP analysis of pyloric function before G-POEM. EndoFLIP can also be used after the procedure, but the swelling and inflammation may affect the measurements. Therefore, this technology may play a role when performed before G-POEM to define who would benefit from pyloric intervention, but further studies are needed to validate its use.

Another risk factor of the response to the G-POEM procedure was also reported by Gonzalez et al. [25] and suggests that diabetes and female gender were associated with a poor response while idiopathic and postoperative etiologies were predictive of success. Diabetes is a complex disease that affects not only the stomach but also the small bowel, explaining why it leads to worse outcomes. When we compared these results with those using gastric electrical stimulation, which has demonstrated better outcomes in the diabetic population, with better glycemic control and lower hemoglobin A1c levels, as well as more consistent symptom improvement in the diabetic (vs. idiopathic) subgroup [34, 45], in the future, we may rely on a

► **Table 5** Adverse events severity.

Study	Adverse events (procedure-related)	Adverse event (type)	Severity
Rodriguez J. et al, 2018	10	4 bleeding 1 capnoperitoneum and subcutaneous emphysema (diagnostic laparoscopy) 2 severe dehydration 3 repeat upper endoscopy	Moderate Severe Moderate Moderate
Landreneau et al, 2018	1	1 abdominal pain (needed diagnostic laparoscopy)	Severe
Malik Z. et al, 2018	1	1 pulmonary embolism	Severe
Gonzalez J.M. et al, 2017	9	4 pneumoperitoneum 1 pneumoperitoneum and abscess 2 bleeding 1 stricture (delayed)	Mild Severe Moderate Moderate
Xue H.B. et al, 2017	0	none	–
Mekaroonkamol P. et al, 2019	3	1 tension capnoperitoneum 1 bleeding ulcer 1 exacerbation of pre existing chronic obstructive pulmonary disease	Mild Moderate Moderate
Hustak R. et al, 2018	1	1 bleeding ulcer	Moderate
Dacha S. et al, 2017	1	1 tension pneumoperitoneum	Mild
Hernandez-Mondragon O.V. et al, 2017	4	4 abdominal pain	Mild
Jacques J. et al, 2019	28	(8 not related to G-POEM) 3 gastric perforation 1 abdominal pain (needed reoperation) 8 procedural abdominal pain 1 epistaxis 7 GI bleeding	Mild Severe Mild Mild Moderate

personalized therapeutic approach depending on the etiology to lead to better outcomes. Further randomized studies are needed to be performed to confirm these results.

The post-procedure 4-hour gastric emptying scintigraphy was performed in all 10 studies, and there was significant variability in these improvement results. Hustak et al. [20] reported that GES was normalized in all patients (100%), while Xue et al. [26] demonstrated a decrease in GES of 83%. In the Gonzalez et al. [24] study, GES was normalized in 70% of cases. However, comparing the mean values before and after the intervention, a significant improvement was found in the mean half emptying time but not in the residual percentage at 4-hour GES. This discordance rate was 21%, in favor of a clinical improvement despite disturbed GES, except for one case. Landreneau et al. [1] compared G-POEM with laparoscopic pyloroplasty and showed no difference in this outcome between the two procedures ($P=0.907$); most patients showed improved GES after undergoing either G-POEM or laparoscopic pyloroplasty (85.7 vs. 83.3%). However, normal gastric emptying does not seem to be necessary for a good symptomatic response, and, together with the GSCI score, are the only two parameters to measure clinical success in most studies; the improvement in GES (or both) after G-POEM was achieved, with high rates, as related above. Because there is no consensus regarding how to define the therapeutic success of gastroparesis treatment, Mekaroonkamol et

al. [23] proposed that the clinical criteria to undergo the G-POEM procedure should be a baseline GCSI of at least 2.0 and a GES gastric retention rate greater than 20% at 4 hour.

Finally, to suggest that G-POEM is a safe procedure, gastrointestinal bleeding was the most common event (32%), followed by abdominal pain (30%) and pneumoperitoneum (24%). Bleeding gastrointestinal cases were treated by endoscopy, while the abdominal pain treatment was considered severe in 4 cases (4/11) and needed diagnostic laparoscopy [1, 19, 22, 25] (► **Fig. 8**). No related death occurred, except for the death of a patient in Rodriguez et al. study and one patient in Landreneau et al. study [1, 19]. However, on autopsy, these deaths were determined to be related to underlying cardiac disease. Adverse events were classified according to Cotton et al [46] as mild, moderate, and severe as shown in ► **Table 5**.

Limitations

We conducted a comprehensive literature search and included all the available data in this regard. Our meta-analysis is weakened by limitations inherent to meta-analyses and the included studies. Furthermore, most of the data were derived from observational studies, with all of them being of very low-quality evidence. G-POEM is a novel technique with promising outcomes. However, we still cannot affirm for how long symptoms will remain improved, a situation likely to be explained, in part,

by the short follow-up duration of the studies. The heterogeneity encountered in GCSI analysis was still high, even excluding the outlier study that presented a publication bias. However, all the studies showed a decrease in the values of GCSI and improved symptoms, indicating that the heterogeneity may be due to different population numbers ($n=7-100$), baseline severity of the disease and follow-up periods (1 m–18 m) across each study and not to the effects. GES heterogeneity was also high, and all the studies improved GES as well. Finally, there were other limitations in the present study including its retrospective design and that the experienced endoscopists performed most of the procedures.

Conclusion

G-POEM is effective, safe, minimally invasive and shows promising outcomes in the clinical response and gastric emptying studies. This procedure must be in the arsenal of treatment options for refractory gastroparesis; when performed by experienced hands, it shows a low risk of adverse events. However, there are only short- and mid-term efficacy studies; further controlled trials are needed to predict those who respond best to this treatment and to establish the long-term efficacy of this technique.

Competing interests

The authors declare that they have no conflict of interest.

References

- [1] Landreneau JP, Strong AT, El-Hayek K et al. Laparoscopic pyloroplasty versus endoscopic per-oral pyloromyotomy for the treatment of gastroparesis. *Surg Endosc* 2019; 33: 773–781
- [2] Parkman HP, Hasler WL et al. American Gastroenterological Association technical review on the diagnosis and treatment of gastroparesis. *Gastroenterology* 2004; 127: 1592–1622
- [3] Camilleri M, Parkman HP, Shafi MA et al. Clinical guideline: management of gastroparesis. *Am J Gastroenterol* 2013; 108: 18–37;38
- [4] Oh JH, Pasricha PJ. Recent advances in the pathophysiology and treatment of gastroparesis. *J Neurogastroenterol Motil* 2013; 19: 18–24
- [5] Xu J, Chen T, Elkholy S et al. Gastric peroral endoscopic myotomy (G-POEM) as a treatment for refractory gastroparesis: long-term outcomes. *Can J Gastroenterol Hepatol* 2018; 2018: 6409698
- [6] Jones MP, Maganti K. A systematic review of surgical therapy for gastroparesis. *Am J Gastroenterol* 2003; 98: 2122–2129
- [7] Arts J, Holvoet L, Caenepeel P et al. Clinical trial: a randomized-controlled crossover study of intrapyloric injection of botulinum toxin in gastroparesis. *Aliment Pharmacol Ther* 2007; 26: 1251–1258
- [8] FriedenberG FK, Palit A, Parkman HP et al. Botulinum toxin A for the treatment of delayed gastric emptying. *Am J Gastroenterol* 2008; 103: 416–423
- [9] Ahuja NK, Clarke JO. Pyloric therapies for gastroparesis. *Curr Treat Options Gastroenterol* 2017; 15: 230–240
- [10] Khashab MA, Besharati S, Ngamruengphong S et al. Refractory gastroparesis can be successfully managed with endoscopic transpyloric stent placement and fixation (with video). *Gastrointest Endosc* 2015; 82: 1106–1109
- [11] Clarke JO, Snape WJ. Pyloric sphincter therapy: botulinum toxin, stents, and pyloromyotomy. *Gastroenterol Clin North Am* 2015; 44: 127–136
- [12] Kawai M, Peretta S, Burckhardt O et al. Endoscopic pyloromyotomy: a new concept of minimally invasive surgery for pyloric stenosis. *Endoscopy* 2012; 44: 169–173
- [13] Chaves DM, Gusmon CC, Mestieri LHM et al. A new technique for performing endoscopic pyloromyotomy by gastric submucosal tunnel dissection. *Surg Laparosc Endosc Percutan Tech* 2014; 24: 92–94
- [14] Khashab MA, Stein E, Clarke JO et al. Gastric peroral endoscopic myotomy for refractory gastroparesis: first human endoscopic pyloromyotomy (with video). *Gastrointest Endosc* 2013; 78: 764–768
- [15] Chaves DM, de Moura EGH, Mestieri LHM et al. Endoscopic pyloromyotomy via a gastric submucosal tunnel dissection for the treatment of gastroparesis after surgical vagal lesion. *Gastrointest Endosc* 2014; 80: 164
- [16] Moher D, Shamseer L, Clarke M et al. Preferred reporting items for systematic review and meta-analysis protocols (PRISMA-P) 2015 statement. *Syst Rev* 2015; 4: 1
- [17] Stroup DF, Berlin JA, Morton SC et al. Meta-analysis of observational studies in epidemiology: a proposal for reporting Meta-analysis Of Observational Studies in Epidemiology (MOOSE) group. *JAMA* 2000; 283: 2008–2012
- [18] Guyatt GH, Oxman AD, Vist GE et al. GRADE: an emerging consensus on rating quality of evidence and strength of recommendations. *BMJ* 2008; 336: 924–926
- [19] Rodriguez J, Strong AT, Haskins IN et al. Per-oral pyloromyotomy (POP) for medically refractory gastroparesis: short term results from the first 100 patients at a high volume center. *Ann Surg* 2018; 268: 421–430
- [20] Hustak R, Vackova Z, Rabeckova Z et al. Per-oral endoscopic pyloromyotomy (G-poem) in the treatment of refractory gastroparesis-mid-term single centre experience. *Gastrointest Endosc [Internet]* 2018; 87: AB304–AB305
- [21] Hernandez Mondragon OV, Palos Cuellar R, Blanco Velasco G et al. Gastric per-oral endoscopic pyloromyotomy (G-POEM) in the treatment of refractory gastroparesis: Experience of the first 9 cases in a Mexico United. *Eur Gastroenterol J [Internet]* 2017; 5: A442
- [22] Jacques J, Pagnon L, Hure F et al. Peroral endoscopic pyloromyotomy is efficacious and safe for refractory gastroparesis: prospective trial with assessment of pyloric function. *Endoscopy* 2019; 51: 40–49
- [23] Mekaroonkamol P, Patel V, Shah R et al. Association between duration or etiology of gastroparesis and clinical response after gastric per-oral endoscopic pyloromyotomy. *Gastrointest Endosc* 2019; 5: 969–976
- [24] Malik Z, Kataria R, Modayil R et al. Gastric per oral endoscopic myotomy (G-POEM) for the treatment of refractory gastroparesis: early experience. *Dig Dis Sci* 2018; 63: 2405–2412
- [25] Gonzalez JM, Benezech A, Vitton V et al. G-POEM with antro-pyloromyotomy for the treatment of refractory gastroparesis: mid-term follow-up and factors predicting outcome. *Aliment Pharmacol Ther* 2017; 46: 364–370
- [26] Xue HB, Fan HZ, Meng XM et al. Fluoroscopy-guided gastric peroral endoscopic pyloromyotomy (G-POEM): a more reliable and efficient method for treatment of refractory gastroparesis. *Surg Endosc* 2017; 31: 4617–4624
- [27] Dacha S, Mekaroonkamol P, Li L et al. Outcomes and quality-of-life assessment after gastric per-oral endoscopic pyloromyotomy (with video). *Gastrointest Endosc [Internet]* 2017; 86: 282–289
- [28] Dacha S, Mekaroonkamol P, Li L et al. Outcomes and quality-of-life assessment after gastric per-oral endoscopic pyloromyotomy (with video). *Gastrointest Endosc* 2017; 86: 282–289

- [29] Rao AS, Camilleri M. Review article: metoclopramide and tardive dyskinesia. *Aliment Pharmacol Ther* 2010; 31: 11–19
- [30] Schey R, Saadi M, Midani D et al. Domperidone to treat symptoms of gastroparesis: benefits and side effects from a large single-center cohort. *Dig Dis Sci* 2016; 61: 3545–3451
- [31] Khashab MA, Ngamruengphong S, Carr-Locke D et al. Gastric per-oral endoscopic myotomy for refractory gastroparesis: results from the first multicenter study on endoscopic pyloromyotomy (with video). *Gastrointest Endosc* 2017; 85: 123–128
- [32] Zoll B, Zhao H, Edwards MA et al. Outcomes of surgical intervention for refractory gastroparesis: a systematic review. *J Surg Res* 2018; 231: 263–269
- [33] Lal N, Livemore S, Dunne D et al. Gastric electrical stimulation with the enterra system: a systematic review. *Gastroenterol Res Pract* 2015; 2015: 762972
- [34] Abell T, McCallum R, Hocking M et al. Gastric electrical stimulation for medically refractory gastroparesis. *Gastroenterology* 2003; 125: 421–428
- [35] Bortolotti M. Gastric electrical stimulation for gastroparesis: a goal greatly pursued, but not yet attained. *World J Gastroenterol* 2011; 17: 273–282
- [36] Hibbard ML, Dunst CM, Swanstrom LL. Laparoscopic and endoscopic pyloroplasty for gastroparesis results in sustained symptom improvement. *J Gastrointest Surg* 2011; 15: 1513–1519
- [37] Mekaroonkamol P, Shah R, Cai Q. Outcomes of per oral endoscopic pyloromyotomy in gastroparesis worldwide. *World J Gastroenterol* 2019; 25: 909–922
- [38] Jones MP, Maganti K. A systematic review of surgical therapy for gastroparesis. *Am J Clin Gastroenterol* 2003; 98: 2122–2129
- [39] Toro JP, Lytle NW, Patel AD et al. Efficacy of laparoscopic pyloroplasty for the treatment of gastroparesis. *J Am Coll Surg* 2014; 218: 652–660
- [40] Kahaleh M, Gonzalez J-M, Xu M-M et al. Gastric peroral endoscopic myotomy for the treatment of refractory gastroparesis: a multicenter international experience. *Endoscopy* 2018; 50: 10531058
- [41] Lambdin JT, Zeddun S, Borum ML. Role of laparoscopic-assisted gastric per-oral endoscopic pyloromyotomy in refractory gastroparesis. *Digest Dis Sci* 2018; 63: 1366
- [42] Shlomovitz E, Pescarus R, Cassera MA et al. Early human experience with per-oral endoscopic pyloromyotomy (POP). *Surg Endosc* 2015; 29: 543–551
- [43] Allemang MT, Strong AT, Haskins IN et al. How I do it: per-oral pyloromyotomy (POP). *J Gastrointest Surg* 2017; 21: 1963–1968
- [44] Cai MY, Xu JX, We-Zhebg Q et al. Gastric peroral endoscopic myotomy (G-POEM) as treatment for functional delayed gastric emptying: initial Asian experience. *J Gastroenterol Hepatol [Internet]* 2017; 32: 241–242
- [45] McKenna D, Beverstein G, Reichelderfer M et al. Gastric electrical stimulation is an effective and safe treatment for medically refractory gastroparesis. *Surgery* 2008; 144: 564–566
- [46] Cotton PB, Eisen GM, Aabakken L et al. A lexicon for endoscopic adverse events: report of an ASGE workshop. *Gastrointest Endosc* 2010; 71: 446–454