

Novel intragastric trocar placement by percutaneous endoscopic gastrostomy technique to facilitate pyloromyotomy

Motility disorders of the stomach, such as gastroparesis, are commonly encountered in clinical practice [1]. The treatment of these disorders remains controversial. Although surgery is usually reserved for patients with chronic and severe symptoms refractory to medical therapy, the true benefit and risk profiles remain unclear [2]. Recently, a new endoscopic technique, termed gastric peroral endoscopy myotomy (G-POEM) has been described. This technique has shown promising results. However, G-POEM is technically challenging and highly dependent on the skill of the endoscopist. To date, several variations of this procedure have been reported [3].

Given the limitations of available treatment modalities, we demonstrate an endoscopic approach in a porcine model using a novel gastric access device (► Fig. 1, ► Video 1) that allows the use of standard laparoscopic tools to perform pyloromyotomy. This device was previously described by our group for gastric resection [4, 5].

Under endoscopic visualization, an intragastric port (Endo-TAGSS, Leakwood, Kansas, USA) was placed in a fashion similar to that adopted for standard percutaneous endoscopic gastrostomy. Then, the dilator tip was replaced with a trocar head and connected to a laparoscopic insufflator. A laparoscopic stapler was advanced through the port to linearly section the antero-lateral portion of the pylorus (► Fig. 2, ► Fig. 3). The port was then removed, and the gastric access was closed with two cap-mounted clips (► Fig. 4). Finally, the peritoneum and skin defect were sutured with nylon.

The animal received 2 days of liquid diet post-procedure followed by a regular diet. It was housed in the laboratory facility for 15 days and did not experience any adverse events. Necropsy revealed a healed gastric access site and an intact staple line on the serosa of the pylorus, confirming full-thickness myotomy (► Fig. 5).

In conclusion, this novel technique may provide a feasible alternative, retaining

the advantages of both endoscopic and laparoscopic approaches, while being a less invasive procedure than laparoscopic pyloroplasty.

Endoscopy_UCTN_Code_TTT_1AO_2AK

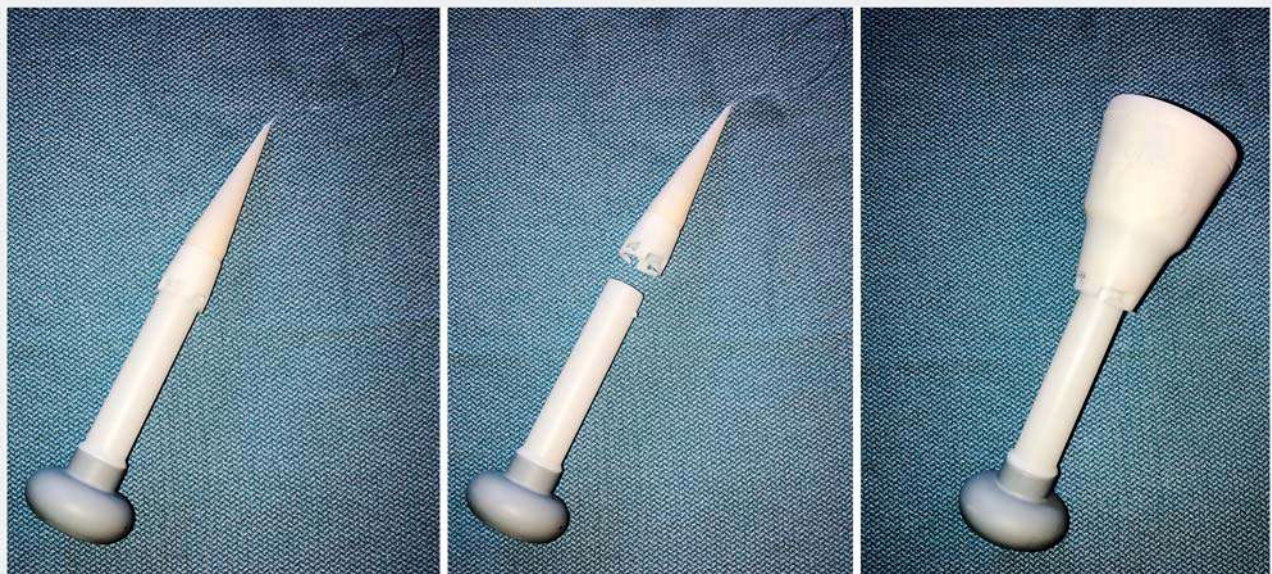
Competing interests

Dr. Thompson is a consultant for TAGSS, Boston Scientific, Apollo Endosurgery, and Olympus. Dr. Aihara is a consultant for Fujinon and Boston Scientific.

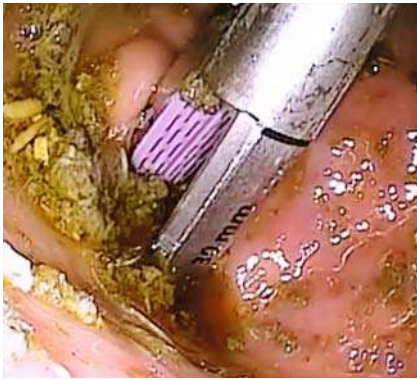The authors

Diogo Turiani Hourneaux de Moura, Hiroyuki Aihara, Ahmad Najdat Bazarbashi, Christopher C. Thompson

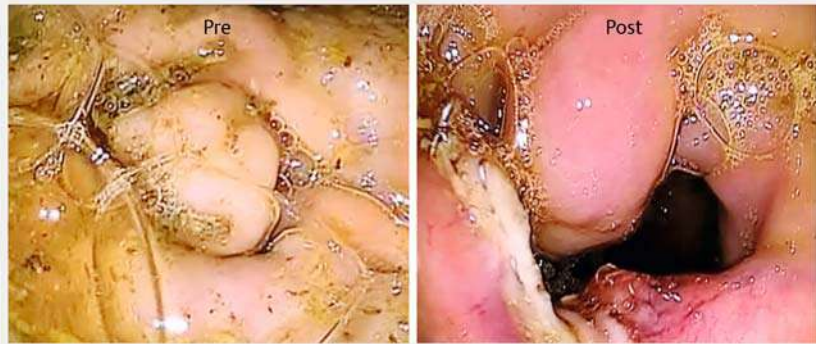Division of Gastroenterology, Hepatology and Endoscopy, Brigham and Women's Hospital, Harvard Medical School, Boston, Massachusetts, United States



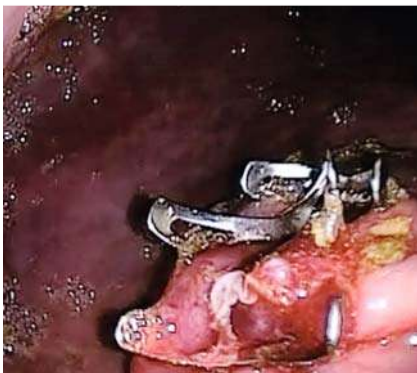► Fig. 1 Transabdominal surgical system (TAGSS) ports (Endo-TAGSS, Leakwood, Kansas, USA).



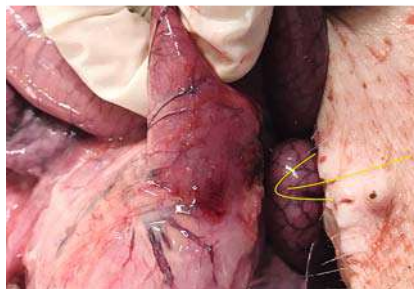
► **Fig. 2** Pyloromyotomy with laparoscopic staple assistance.



► **Fig. 3** Pre- and post-procedure pylorus images.



► **Fig. 4** Gastric access closed with two over-the-scope clips.



► **Fig. 5** Necropsy revealed a healed gastric access site and an intact staple line on the serosa of the pylorus (arrow), confirming full-thickness myotomy.

Corresponding author

Christopher C. Thompson, MD, MS

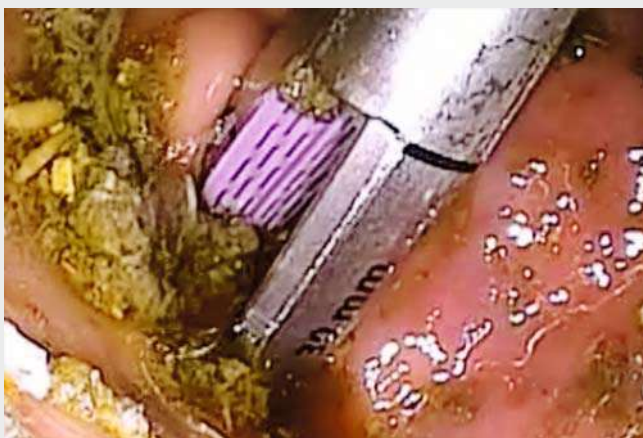Division of Gastroenterology, Hepatology and Endoscopy, Brigham and Women's Hospital, 75 Francis St., Thorn 1404, Boston, MA 02115, United States
 Fax: +1-617-264-6342
 cthompson@hms.harvard.edu

References

- [1] Liu N, Abell T. Gastroparesis updates on pathogenesis and management. *Gut Liver* 2017; 11: 579–589
- [2] Tsai CH, Liou GJ, Liu CL et al. Surgical management of benign gastric outlet obstruction in the elderly. *Hepatogastroenterology* 2012; 59: 1643–1646
- [3] Tao J, Patel V, Mekaroonkamol P et al. Technical aspects of peroral endoscopic pyloromyotomy. *Gastrointest Endosc Clin N Am* 2019; 29: 117–126
- [4] Storm AC, Aihara H, Thompson CC. Novel intragastric trocar placed by PEG technique permits endolumenal use of rigid instruments to simplify complex endoscopic procedures. *Gastrointest Endosc* 2016; 84: 518–522
- [5] Storm AC, Aihara H, Skinner MJ et al. Long-term successful closure of a percutaneous intragastric trocar tract with crossing full-thickness sutures in a porcine model. *Endoscopy* 2018; 50: 626–630

Bibliography

DOI <https://doi.org/10.1055/a-0985-3995>
 Published online: 2019
 Endoscopy
 © Georg Thieme Verlag KG
 Stuttgart · New York
 ISSN 0013-726X



► **Video 1** Pyloromyotomy with laparoscopic staple assistance.

