

# ENDOSCOPIC ULTRASOUND IN THE EVALUATION OF UPPER SUBEPITHELIAL LESIONS

Dalton Marques **CHAVES**, Gilmara Coelho **MEINE**, Diogo Turiani Hourneaux de **MOURA**, Sergio Eiji **MATUGUMA**, Marcos Eduardo **LERA**, Everson Luiz de Almeida **ARTIFON**, Eduardo Guimarães Hourneaux de **MOURA** and Paulo **SAKAI**

Received 28/12/2014  
Accepted 24/3/2015

**ABSTRACT - Background** - Endoscopic ultrasound is considered the best imaging test for the diagnosis and evaluation of subepithelial lesions of the gastrointestinal tract. **Objective** - The present study aims to describe the endosonographic characteristics of upper gastric subepithelial lesions and our experience using endoscopic ultrasound for evaluation of such lesions. **Methods** - Retrospective data study of 342 patients who underwent endoscopic ultrasound evaluation of subepithelial lesions. **Results** - Lesions of the fourth layer were more common in the stomach (63.72%) than in the esophagus (44.68%) and duodenum (29.03%). In stomach, 81.1% of the lesions  $\geq 2$  cm, and 96.5%  $\geq 3$  cm, were from the fourth layer. Endosonographic signs that could be related to malignant behavior, such as irregular borders, echogenic foci, cystic spaces and/or size greater than 3 cm were identified in 34 (15.81%) lesions at the first endoscopic ultrasound evaluation. Endoscopic ultrasound-fine needle aspiration did the diagnosis in 21 (61.76%) patients who were submitted a puncture. Three (12.0%) lesions of 25 who were submitted to regular endoscopic ultrasound surveillance increased the size. **Conclusion** - Stomach is the organ most affected with subepithelial lesions of the gastrointestinal tract and the fourth layer was the most common layer of origin. More than 80% of gastric subepithelial lesions from the fourth layer are  $\geq 2$  cm. Endoscopic ultrasound evaluation of subepithelial lesions has been very important for stratification into risk groups and to determine the best management. **HEADINGS** - Endosonography. Gastrointestinal stromal tumors. Endoscopic ultrasound-guided fine needle aspiration. Biopsy fine-needle.

## INTRODUCTION

The term subepithelial lesion is applied to a mass or bulge covered by normal-appearing mucosa usually identified incidentally during esophagogastroduodenoscopy (EGD). The incidence of gastric subepithelial lesions (GSLs) in patients undergoing routine EGD was reported as 0.36%<sup>(6)</sup> and the stomach is the organ most frequently affected.

The differential diagnosis of a subepithelial mass includes gastrointestinal stromal tumors (GISTs), leiomyoma, lipoma, pancreatic rest, duplication cysts, inflammatory fibroid polyps, carcinoid tumors, varices, lymphoma, metastasis and extramural lesions. Endoscopic ultrasound (EUS) is the diagnostic test of choice to assess the size, margins, layer of origin, echo texture of the lesion, presence of adjacent lymph nodes and to distinguish between intramural and extramural lesions<sup>(8)</sup>. Furthermore, EUS is consistently superior to other imaging tests for the diagnosis and

evaluation of subepithelial lesions of the gastrointestinal tract<sup>(15, 16)</sup>. EUS alone has been shown to have a sensitivity and specificity of 64% and 80%, respectively, in the distinction between malignant and benign subepithelial lesions<sup>(16)</sup> and the combination of EUS and fine needle aspiration (FNA) allows cytologic evaluation of GSLs, with studies reporting accuracies of 80% to 91%<sup>(1, 5, 18)</sup>.

The present study aims to describe the endosonographic characteristics of the subepithelial lesions of the upper digestive tract and also our experience using EUS for surveillance of such lesions.

## METHODS

All patients referred to the Gastrointestinal Endoscopy Department of Hospital das Clínicas of São Paulo University, during the last 6 years, who underwent EUS evaluation of subepithelial lesions from the upper digestive tract were taken from the

Declared conflict of interest of all authors: none

Disclosure of funding: no funding received

Unidade de Endoscopia Gastrointestinal, Hospital das Clínicas, Faculdade de Medicina, Universidade de São Paulo, São Paulo, Brasil.

Correspondence: Dalton Marques Chaves. Unidade de Endoscopia Gastrointestinal, Hospital das Clínicas, Universidade de São Paulo, SP, Brasil. Email: chavesdalton@gmail.com

electronic procedure database. Five experienced endoscopists employing a Miniprobe 12 Mhz (Olympus), radial echoendoscope (Olympus) or sectorial echoendoscope (Olympus), performed Endosonographic examination and fine needle puncture guided by EUS (EUS-FNA) at the discretion of each endoscopist. The following data were extracted and entered into an Excel database: sex and age of the patients, location, size and endosonographic characteristics of the GSL, number of EUS examinations, histopathological results, and surgical records if available. For those patients who underwent regular EUS surveillance, any changes in tumor size and EUS characteristics were recorded. In view of possible variations in scanning during measurement of maximal tumor diameter in follow-up examination, only an increase of at least 5 mm was considered to be significant. Patient demographics and subepithelial tumor characteristics were analyzed and statistics were determined for the lesions.

### RESULTS

During the study period, 342 patients underwent EUS for evaluation of subepithelial lesions of the upper gastrointestinal tract. Ninety-five (27.8%) patients had lesions in the esophagus, 215 (62.9%) in the stomach and 32 (9.3%) in the duodenum. The layer of origin of subepithelial lesions along the upper gastrointestinal tract is shown in Figure 1.

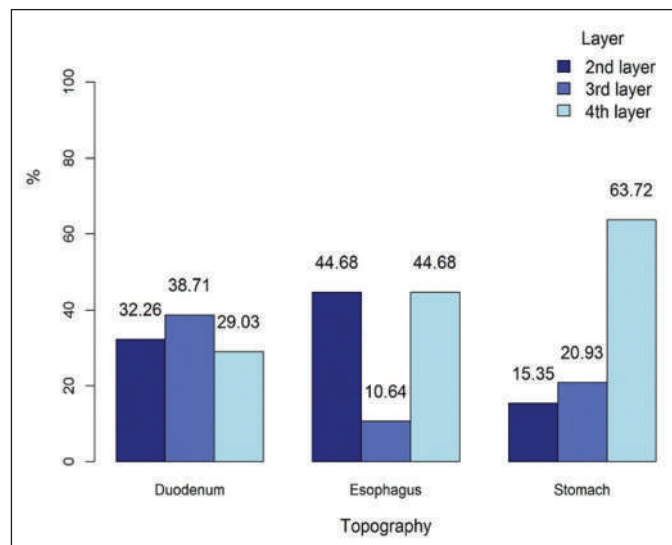


FIGURE 1. Layer of origin of subepithelial lesions of the upper gastrointestinal tract.

Lesions of the fourth layer were more common in the stomach (63.72%) than in the esophagus (44.68%) and duodenum (29.03%) ( $P < 0.001$ ).

Among gastric subepithelial lesions, the fourth layer (muscularis propria) was the most frequently compromised layer, independent of the size of the lesion (Table 1, Figure 2). However, the bigger the lesion was, the higher was the incidence of fourth layer lesions ( $P < 0.005$ ).

TABLE 1. Relationship between gastric subepithelial lesion (GSL) size and compromised layer of the gastric wall

|                       | 2nd layer<br>n (%) | 3rd layer<br>n (%) | 4th layer<br>n (%) | Total<br>n |
|-----------------------|--------------------|--------------------|--------------------|------------|
| GSL < 1 cm            | 21 (23.6%)         | 19 (21.3%)         | 49 (55.1%)         | 89         |
| GSL ≥ 1 cm and < 2 cm | 10 (16.1%)         | 21 (33.9%)         | 31 (50.0%)         | 62         |
| GSL ≥ 2 cm and < 3 cm | 1 (2.7%)           | 6 (16.2%)          | 30 (81.1%)         | 37         |
| GSL ≥ 3 cm            | 1 (3.6%)           | 0 (0.0%)           | 27 (96.4%)         | 28         |
| Total                 | 33 (15.3%)         | 46 (21.3%)         | 137 (63.4%)        | 216        |

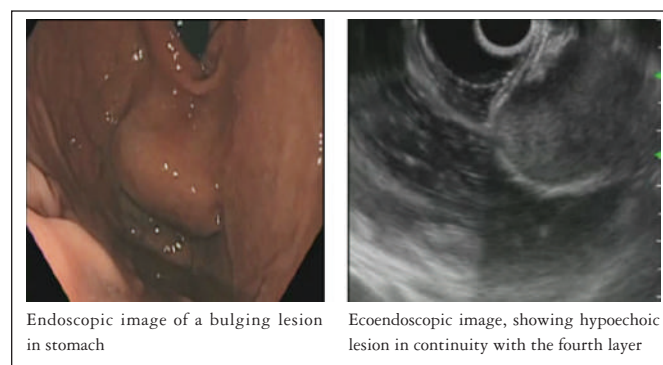


FIGURE 2. Endoscopic and ultrasound image of a gastrointestinal stromal tumors.

Among the patients with GSLs, endosonographic signs that could be related to malignant behavior, such as irregular borders, echogenic foci, cystic spaces and/or size greater than 3 cm, were identified in 34 lesions (15.81%) at the first EUS evaluation.

Of the 34 patients who underwent EUS-FNA at the first EUS evaluation, we had a diagnosis in 21 (61.76%), and 14 (66.67%) of them were GIST. The diagnosis rate was higher for lesions bigger than 3 cm (71.43%) when compared to lesions smaller than 3 cm (57.69%) with  $P < 0.001$  by Fisher test.

Surgical resection at our hospital was performed in four of these patients, confirming GIST in all cases (100% accuracy). An additional four patients, who did not undergo EUS-FNA, had surgery at our hospital and the final diagnosis was GIST for three patients (GSLs of the fourth layer, with a size of 47 mm, 30 mm and 25 mm each) and Schwannoma in one patient (GSL of the fourth layer, 21 mm in size with irregular borders). The other cases with lesions bigger than 3 cm, we missed the follow up, because they were from other hospitals.

Of the 110 patients with GSLs from the fourth layer smaller than 3 cm, 25 (22.7%) patients were submitted to regular EUS surveillance. These patients had an average age of 58.7 years (range 44-82 years), 20 (80%) were women and the mean tumor size determined by EUS was 14.4 mm (range 3-29mm). The average surveillance period was 17.5 months (range 3-41 months), with a mean of 2.2 EUS/patient.

Interval increase in tumor size of at least 5 mm was shown for three patients and all developed endosonographic signs that could be related to malignant behavior (one developed cystic spaces and two lesions reached a size greater than 30 mm). Among the patients with an increase in tumor size, the mean surveillance period was 19.3 months, and all of them were diagnosed with GIST. Detailed information regarding these lesions is shown in Table 2.

### DISCUSSION

Gastric subepithelial lesions are often asymptomatic, usually being discovered incidentally during EGD for unrelated conditions, and the most common GSLs are GISTs. When a GSL is identified, EUS is the diagnostic test of choice. Most GISTs (approximately 60%) arise from muscularis propria in the stomach from the interstitial cells of Cajal<sup>(3, 11)</sup>. The incidence of GISTs is estimated at 1.5/100,000/year<sup>(2)</sup> and 10%-30% are malignant<sup>(4, 12)</sup>. Endosonographic signs that could be related to malignant behavior include large size (>3 cm), irregular borders, cystic spaces or echogenic foci<sup>(7)</sup>. Palazzo et al.<sup>(13)</sup> reported that the presence of at least one of these criterias has a 91% sensitivity of predicting malignant or borderline GIST.

The management options for the GSLs include surgical resection, EUS-FNA and close surveillance. Lee et al.<sup>(9)</sup> suggest a treatment algorithm for patients with GSL (Figure 3) and the American Gastroenterological Association<sup>(7)</sup> recommends surgical resection for GSLs from the fourth layer greater than 3 cm, and follow-up with periodic endos-

copy and/or EUS for GSLs smaller than 3 cm. All GISTs have malignant potential according to the classification system proposed by the National Institutes of Health Consensus Conference<sup>(4)</sup> and this is also the case even for small lesions<sup>(1, 10, 14, 19)</sup>. The authors believe that all GSLs should first be evaluated by endoscopic ultrasound to exclude other evident etiologies (such as lipomas, vascular lesions, pancreatic rest, extra-mural compression) and to determine the most adequate management based on echo-endoscopic findings.

A mean follow-up in our study of 17.5 months, three patients (12%) presented an increase in tumor size (≥5 mm) and all of them developed endosonographic signs that could be related to malignant behavior (a tumor size greater than 30 mm was reached in two patients and one patient developed cystic spaces), suggesting the need for EUS surveillance.

Tissue diagnosis of GSLs should distinguish GIST from other histology lesions and evaluate the malignant potential of any given GIST. Despite the high accuracy of the EUS-FNA, our study presented a low diagnostic yield for lesions smaller than 3 cm (57.69%). The reported diagnostic rate of EUS-FNA for subepithelial tumours <2 cm and ≥2cm is 45% and 80%, respectively<sup>(20)</sup>. Lee et al.<sup>(9)</sup> reported an overall diagnostic rate of 57% with Trucut biopsy (unsuccessful puncture in 14% and inadequate samples in 29% of cases). Considering the technical problems of EUS-FNA and the infrequent metastatic risk in small GISTs smaller than 1 cm, Papanikolaou et al.<sup>(14)</sup> recommended aggressive use of EUS-FNA only for subepithelial hypoechoic tumors of the gastrointestinal tract larger than 1 cm. The diagnostic failure rates for EUS-FNA

TABLE 2. Patients with GSL enlargement during EUS surveillance

| Location     | Gastric body Surveillance (months) | Initial size (mm) | Layer | Increase in size (mm) | Malignant features |
|--------------|------------------------------------|-------------------|-------|-----------------------|--------------------|
| Gastric body | 31                                 | 14                | 4     | 12                    | cystic spaces      |
| Gastric body | 4                                  | 26                | 4     | 5                     | >30 mm             |
| Gastric body | 23                                 | 29                | 4     | 5                     | >30 mm             |

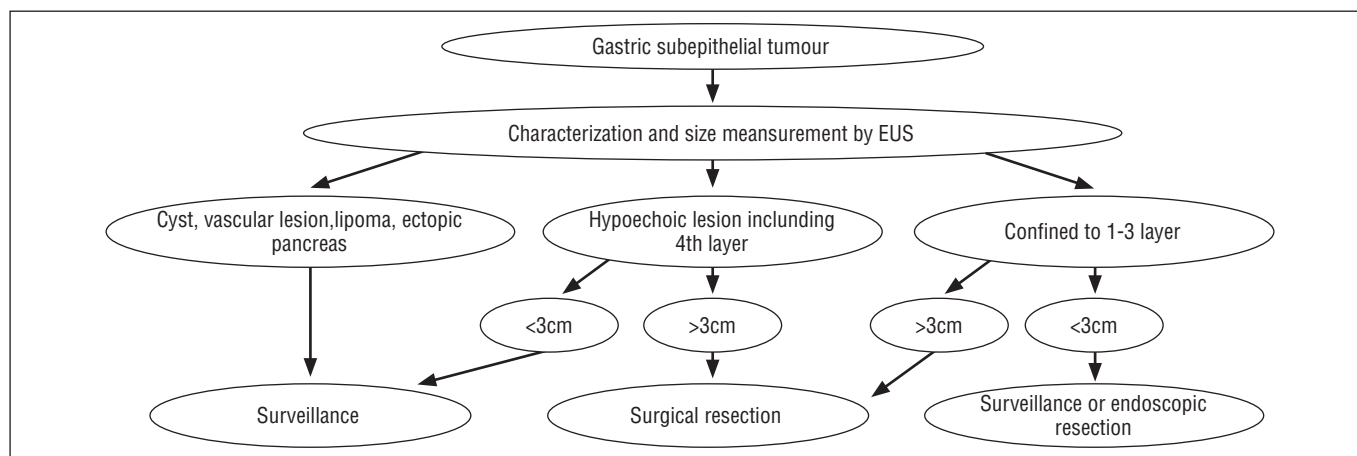


FIGURE 3. Treatment algorithm for patients with GSLs suggested by Lee et al.<sup>(9)</sup>

of small GSLs reported in different studies indicates the need for developing new methods to increase the accuracy of EUS imaging and the diagnostic yield of EUS-FNA. Sakamoto et al.<sup>(17)</sup> have described a sensitivity, specificity, and accuracy of 100%, 63%, and 83%, respectively, to predict GIST malignancies using contrast-enhanced harmonic EUS, making this a promising method.

The limitations of the present study include firstly, the retrospective design. Secondly, although EUS was performed in a single institution, patients came from several centers and were selected for follow-up or surgery according to institutional criteria. Finally, different pathologists evaluated the histological specimens.

In conclusion, the fourth layer of the gastric wall was the most frequent origin of the GSLs, mainly for GSLs greater than 2 cm. Once a GSL is identified, the EUS is an important tool for identifying signs suggestive of malignant behavior and for performing FNA, allowing the stratification of patients into risk groups.

#### Authors' contributions

Chaves DM: made the protocol, data collection, text writing. Meine GC: data collection and text writing. Moura DTH: text writing and statistical analysis. Matuguma SE, Lera ME and Artifon ELA: data collection. Moura EGH and Sakai P: helped to make the protocol.

Chaves DM, Meine GC, Moura DTH, Matuguma SE, Lera ME, Artifon ELA, Moura EGH, Sakai P. Ultrassom endoscópico na avaliação das lesões subepiteliais do trato digestivo alto. *Arq Gastroenterol.* 2015;52(3):186-9.

**RESUMO - Contexto** - A ecoendoscopia é considerada o melhor método de imagem para diagnosticar e avaliar as lesões subepiteliais do trato digestivo.

**Objetivo** - O presente estudo tem como objetivo fazer uma análise dos casos submetidos a ecoendoscopia para avaliação de lesões subepiteliais do trato digestivo alto. **Métodos** - Foram analisados de forma retrospectiva 342 pacientes submetidos a ecoendoscopia para avaliação de lesões subepiteliais.

**Resultados** - Lesões da quarta camada foram mais comuns no estômago (63,72%) do que no esôfago (44,68%) e no duodeno (29,03%). No estômago, 81,1% das lesões > 2 cm, e 96,5% > 3 cm, eram da quarta camada. Sinais endossônográficos que poderiam ser relacionados com o comportamento maligno, como bordas irregulares, focos ecogênicos, espaços císticos e/ou tamanho maior que 3 cm foram identificados em 34 lesões (15,81%) na primeira avaliação com ecoendoscopia. Aspiração por agulha fina guiada por ultrassom endoscópico fez o diagnóstico em 21 (61,76%) dos pacientes que foram submetidos a punção ecoguiada. Três (12,0%) lesões das 25, que foram submetidas a vigilância pela ecoendoscopia, aumentaram de tamanho. **Conclusão** - O estômago é o órgão mais afetado pelas lesões subepiteliais do trato gastrointestinal alto, sendo a camada muscular própria a camada de origem mais comum. Mais de 80% das lesões gástricas subepiteliais da quarta camada são > 2 cm. A avaliação ecoendoscópica das lesões subepiteliais tem sido muito importante para a estratificação em grupos de risco e para determinar a melhor conduta.

**DESCRITORES** - Endossônografia. Tumores do estroma gastrointestinal. Aspiração por agulha fina guiada por ultrassom endoscópico. Biopsias por agulha fina.

#### REFERENCES

- Ando N, Goto H, Niwa Y, Hirooka Y, Ohmiya N, Nagasaka T, Hayakawa T. The diagnosis of GI stromal tumors with EUS-guided fine needle aspiration with immunohistochemical analysis. *Gastrointest Endosc.* 2002;55(1):37-43.
- Casali PG, Jost L, Reichardt P, Schlemmer M, Blay JY; ESMO Guidelines Working Group. Gastrointestinal stromal tumours: ESMO clinical recommendations for diagnosis, treatment and follow-up. *Ann Oncol.* 2009;20(Suppl 4):64-7.
- DeMatteo RP, Lewis JJ, Leung D, Mudan SS, Woodruff JM, Brennan MF. Two hundred gastrointestinal stromal tumors: recurrence patterns and prognostic factors for survival. *Ann Surg.* 2000;231(1):51-8.
- Fletcher CD, Berman JJ, Corless C, Gorstein F, Lasota J, Longley BJ. Diagnosis of gastrointestinal stromal tumors: a consensus approach. *Hum Pathol.* 2002;33(5):459-65.
- Fu K, Eloubeidi MA, Jhala NC, Jhala D, Chhieng DC, Eltoum IE. Diagnosis of gastrointestinal stromal tumor by endoscopic ultrasound-guided fine needle aspiration biopsy - A potential pitfall. *Ann Diagn Pathol.* 2002;6(5):294-301.
- Hedenbro JL, Ekelund M, Wetterberg P. Endoscopic diagnosis of submucosal gastric lesions. The results after routine endoscopy. *Surg Endosc.* 1991;5(1):20-3.
- Hwang JH, Rulyak SD, Kimmey MB; American Gastroenterological Association Institute. American Gastroenterological Association Institute technical review on the management of gastric subepithelial masses. *Gastroenterology.* 2006;130(7):2217-28.
- Karaca C, Turner BG, Cizginer S, Forcione D, Brugge W. Accuracy of EUS in the evaluation of small gastric subepithelial lesions. *Gastrointest Endosc.* 2010;71(4):722-7.
- Lee JH, Choi KD, Kim MY, Choi KS, Kim do H. Clinical impact of EUS-guided Trucut biopsy results on decision making for patients with gastric subepithelial tumors ≥ 2 cm in diameter. *Gastrointest Endosc.* 2011;74(5):1010-8.
- Meesters B, Pauwels PAA, Pijnenburg AM, Vlasveld LT, Repelaer van Driel OJ. Metastasis in a 'benign' duodenal stromal tumour. *Eur J Surg Oncol.* 1998;24(4):334-5.
- Miettinen M, Sarlomo-Rikala M, Lasota J. Gastrointestinal stromal tumours. *Ann Chir Gynaecol.* 1998;87(4):278-81.
- Miettinen M, Sarlomo-Rikala M, Lasota J. Gastrointestinal stromal tumors: recent advances in understanding of their biology. *Hum Pathol.* 1999;30(10):1213-20.
- Palazzo L, Landi B, Cellier C, Cuillerier E, Roseau G, Barbier JP. Endosonographic features predictive of benign and malignant gastrointestinal stromal cell tumours. *Gut.* 2000;46(1):88-92.
- Papanikolaou IS, Triantafyllou K, Kourikou A, Rösch T. Endoscopic ultrasonography for gastric submucosal lesions. *World J Gastrointest Endosc.* 2011;3(5):86-94.
- Ponsaing LG, Kiss K, Loft A, Jensen LI, Hansen MB. Diagnostic procedures for submucosal tumors in the gastrointestinal tract. *World J Gastroenterol.* 2007;13(24):3301-10.
- Rösch T, Kapfer B, Will U, Baronius W, Strobel M, Lorenz R, et al. Accuracy of endoscopic ultrasonography in upper gastrointestinal submucosal lesions: a prospective multicenter study. *Scand J Gastroenterol.* 2002; 37(7):856-62.
- Sakamoto H, Kitano M, Matsui S, et al. Estimation of malignant potential of GI stromal tumors by contrast-enhanced harmonic EUS. *Gastrointest Endosc.* 2011;73(2):227-37.
- Sepe PS, Moparty B, Pitman MB, Saltzman JR, Brugge WR. EUS-guided FNA for the diagnosis of GI stromal cell tumors: sensitivity and cytologic yield. *Gastrointest Endosc.* 2009;70(2):254-61.
- Trupiano JK, Stewart RE, Misick C, Appelman HD, Goldblum JR. Gastric stromal tumors: a clinicopathologic study of 77 cases with correlation of features with nonaggressive and aggressive clinical behaviors. *Am J Surg Pathol.* 2002;26(6):705-14.
- Watson RR, Binmoeller KF, Hamerski CM, Shergill AK, Shaw RE, Jaffee IM. Yield and performance characteristics of endoscopic ultrasound-guided fine needle aspiration for diagnosing upper GI tract stromal tumors. *Dig Dis Sci.* 2011;56(6):1757-62.