

## VIDEO CASE REPORT

## Endoscopic tunneled stricturotomy in the treatment of stenosis after sleeve gastrectomy

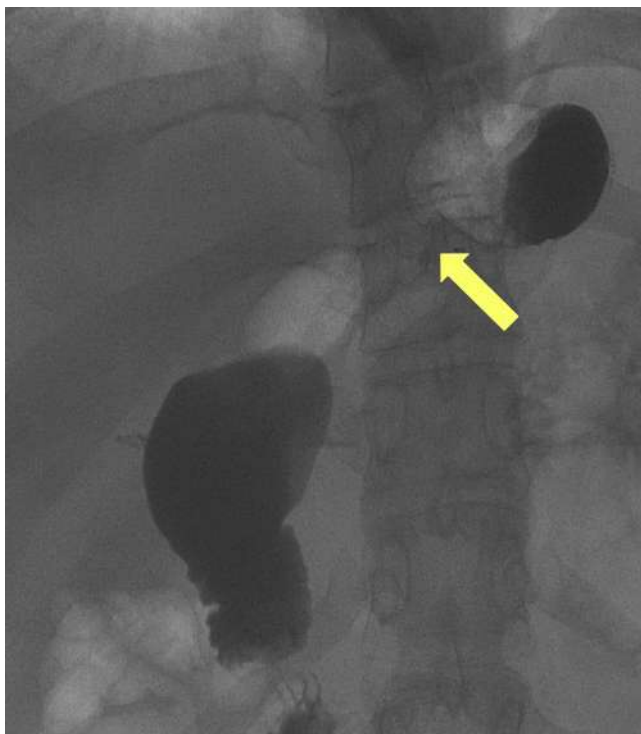Diogo Turiani Hourneaux de Moura, MD, MSc, PhD, Pichamol Jirapinyo, MD, MPH, Hiroyuki Aihara, MD, PhD, Christopher C. Thompson, MD, MHES

Obesity is a worldwide pandemic, and bariatric surgery is the most effective method used to treat this disease. Laparoscopic sleeve gastrectomy (LSG) is rapidly becoming the most commonly performed bariatric surgery because it is perceived as being the “easier technique.” Despite clinical efficacy, adverse events have gradually increased because of its broad adoption.<sup>1-3</sup>

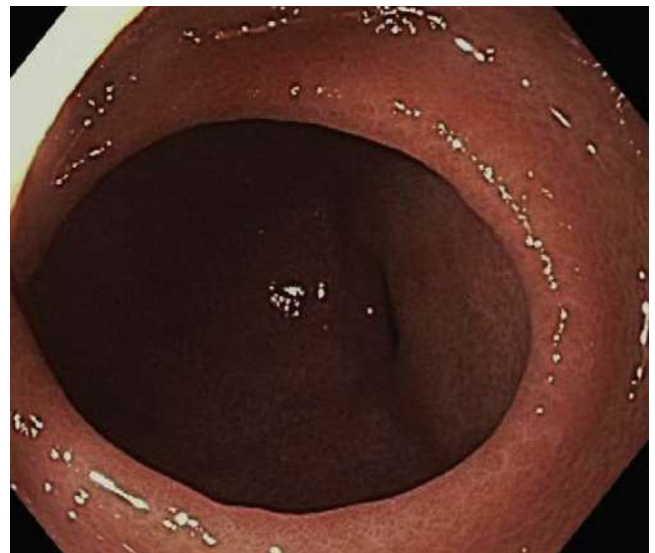
After sleeve leaks, stenosis is the most common adverse event; the incidence is between 0.7% and 4%. Two different entities can cause the obstruction: mechanical stenosis, often in the body of the sleeve, and axial deviation, occurring at the level of the incisura angularis.<sup>2,4,5</sup>

Stenosis can be classified into 2 categories: acute and chronic. Acute stenosis can be caused by mucosal edema and kinking. Chronic stenosis is related to ischemia of the pouch and retraction due to scarring. Clinically, these patients present with obstructive symptoms such as

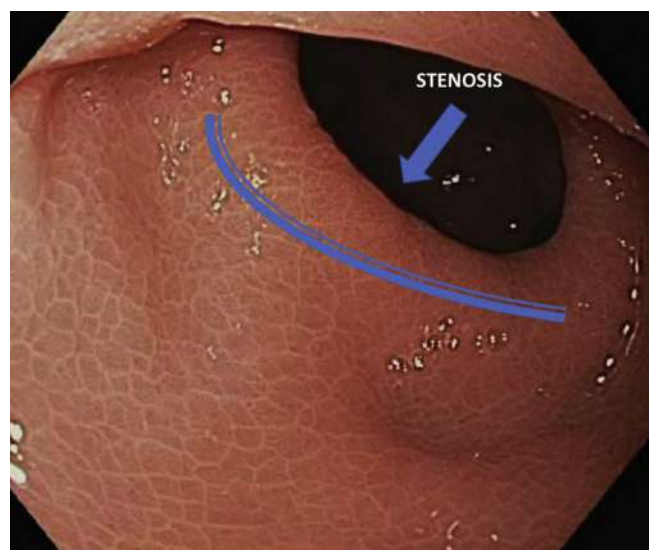
nausea, vomiting, retrosternal burning, epigastric pain, early satiety, and rapid weight loss. To confirm the diagnosis of gastric sleeve stenosis, radiologic imaging and upper-GI endoscopy are essential.<sup>2,4</sup>



**Figure 1.** Upper-GI series demonstrating stenosis after sleeve gastrectomy.



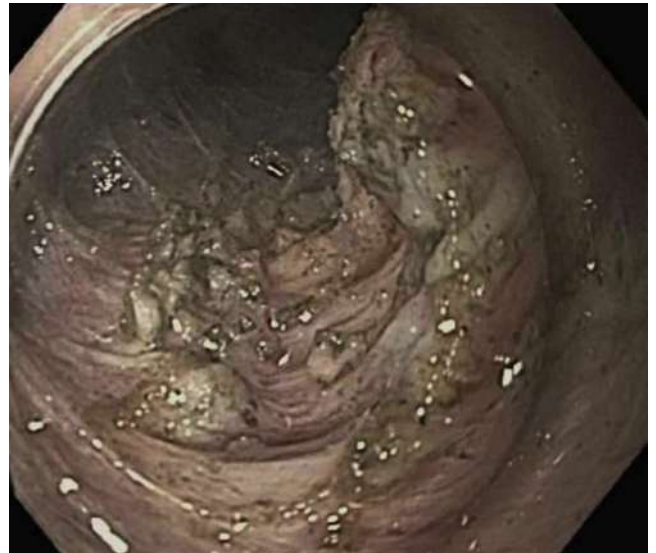**Figure 2.** Sleeve gastrectomy stenosis identification during EGD.



**Figure 3.** Closer view of the stenosis at the level of incisura angularis during EGD.



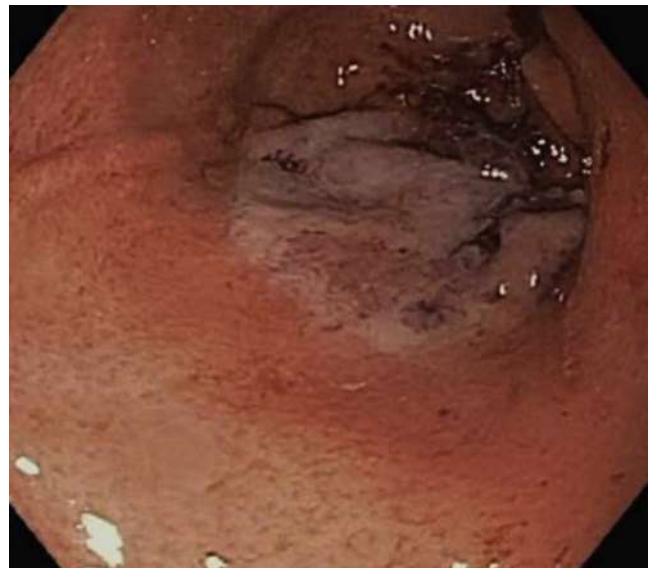**Figure 4.** Submucosal tunnel dissection.



**Figure 6.** Appearance of stricturotomy.



**Figure 5.** Identification of the muscular fibers during submucosal tunneling.



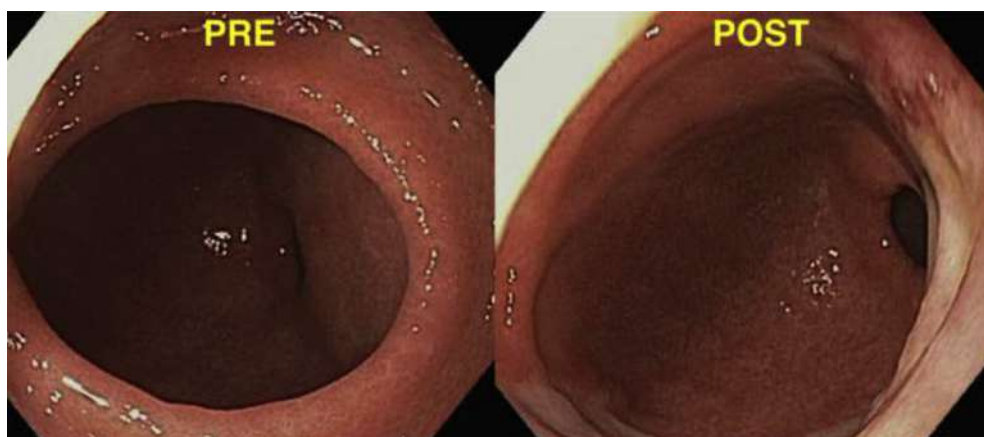
**Figure 7.** Mucosal closure after endoscopic suturing.

Endoscopic management with achalasia balloon dilation (ABD), stent placement, or both, is a less invasive method, recently used to treat LSG stenosis. Some reports show a success rate ranging from 41.4% to 86.6% for ABD. However, ABD is not suitable in some cases because of the length of the stenosis or the length of the gastric sleeve. In addition, in most patients, several sessions are required to relieve the stenosis. Fully covered metal stents have a role in resistant cases; however, they are associated with a high risk of migration: up to 28.2%.<sup>2-6</sup>

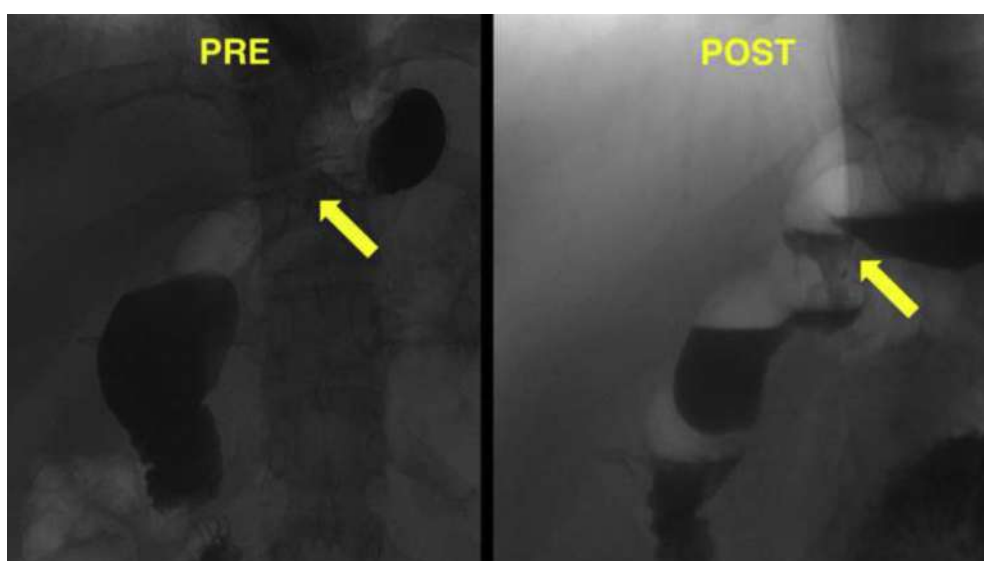
Currently, the surgical options after endoscopic treatment include Roux-en-Y gastric bypass conversion and se-

romyotomy, which have high success rates; however, they are also associated with high adverse event rates, with leaks being one of the most frequent.<sup>5</sup>

Because endoscopic therapies are not always effective in treating stenosis after LSG and because surgical seromyotomy is associated with a high adverse event rate, we describe a new technique. This technique is an endoscopic tunneled stricturotomy and is based on the principles of per-oral endoscopic myotomy. This appears to be a new option in the noninvasive treatment of post-LSG stenosis.<sup>2,4,6,7</sup>



**Figure 8.** Before and after upper-GI endoscopy.



**Figure 9.** Before and after upper-GI series.

We present the case of a 22-year-old obese woman with a history of LSG (Video 1, available online at [www.VideoGIE.org](http://www.VideoGIE.org)). The surgery was uncomplicated; however, the patient was slow in advancing her diet. For the first 2 weeks, she was able to tolerate a liquid diet without any symptoms. However, in the third week, when her diet was advanced to soft food, she began to experience severe nausea and vomiting. Vomiting usually occurred immediately or within half an hour after she had eaten a meal.

She underwent EGD, and stenosis at the level of the incisura was noted. An achalasia balloon (10 cm in length) dilation to 30 mm was performed (Fig. 1). Unfortunately, because of her short 8-cm sleeve, her gastroesophageal junction was also dilated. After the procedure, the patient did not respond and continued to have difficulty with any oral intake of solids.

An upper-GI series (barium swallow) demonstrated stenosis at the level of the incisura (Fig. 2). She was referred for a repeat therapeutic endoscopy. Because the achalasia balloon was too long, the endoscopic tunneled stricturotomy was used.

This new endoscopic tunneled stricturotomy technique is performed in 4 steps: (1) identification of the precise location of stenosis (Fig. 3); (2) submucosal injection approximately 5 cm before the stenotic area; (3) submucosal tunneling stricturotomy (Figs. 4-7); and (4) closure (Fig. 8).

This procedure was technically successful and without adverse events. During follow-up, the patient tolerated an oral diet well, maintaining an 800- to 1000-calorie diet without recurrence of symptoms. An upper-GI series demonstrated significant improvement of the stenosis (Fig. 9).

Endoscopic tunneled stricturotomy appears technically feasible and safe. This technique may offer an alternative option for patients in whom balloon dilation is not indicated or has been unsuccessful. Additional studies are necessary to prove its efficacy.

## DISCLOSURE

*Dr Aihara is a consultant for Boston Scientific and Olympus. Dr Thompson is a consultant for Boston Scientific, Olympus, and Apollo Endosurgery. All other authors disclosed no financial relationships relevant to this publication.*

*Abbreviations: ABD, achalasia balloon dilation; LSG, laparoscopic sleeve gastrectomy.*

## REFERENCES

1. Schulman AR, Thompson CC. Complications of bariatric surgery: what you can expect to see in your GI practice. *Am J Gastroenterol* 2017;112:1640-55.
2. Agnihotri A, Barola S, Hill C, et al. An algorithmic approach to the management of gastric stenosis following laparoscopic sleeve gastrectomy. *Obes Surg* 2017;27:2628-36.
3. Okazaki O, Bernardo WM, Brunaldi VO, et al. Efficacy and safety of stents in the treatment of fistula after bariatric surgery: a systematic review and meta-analysis. *Obes Surg* 2018;28:1788-96.
4. Deslauriers V, Beauchamp A, Garofalo F, et al. Endoscopic management of post-laparoscopic sleeve gastrectomy stenosis. *Surg Endosc* 2018;32:601-9.
5. Dapri G, Cadière GB, Himpens J. Laparoscopic seromyotomy for long stenosis after sleeve gastrectomy with or without duodenal switch. *Obes Surg* 2009;19:495-9.
6. Zundel N, Hernandez JD, Galvao Neto M, et al. Strictures after laparoscopic sleeve gastrectomy. *Surg Laparosc Endosc Percutaneous Tech* 2010;20:154-8.
7. Barbieri LA, Hassan C, Rosati R, et al. Systematic review and meta-analysis: efficacy and safety of POEM for achalasia. *United European Gastroenterol J* 2015;3:325-34.

Brigham and Women's Hospital, Harvard Medical School, Boston, Massachusetts, USA.

Copyright © 2018 American Society for Gastrointestinal Endoscopy. Published by Elsevier Inc. This is an open access article under the CC BY-NC-ND license (<http://creativecommons.org/licenses/by-nc-nd/4.0/>).

<https://doi.org/10.1016/j.vgie.2018.09.013>