

Endoscopic management of acute leak after sleeve gastrectomy: principles and techniques

ENDOSCOPIC TECHNIQUES FOR POST-BARIATRIC SURGERY LEAKS AND FISTULAS

CLOSURE

- Glues/Tissue sealants
- Cap-mounted clips
- Suturing

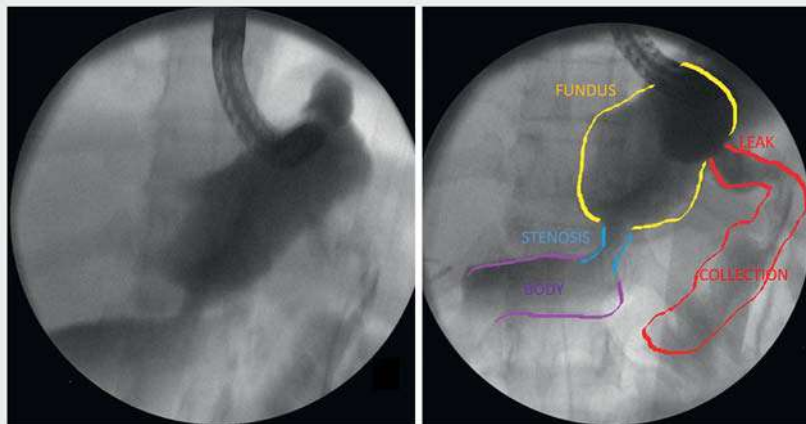
COVERING

- Stents
- Conventional esophageal or specific design for LSG
- Cardiac septal defect occluder

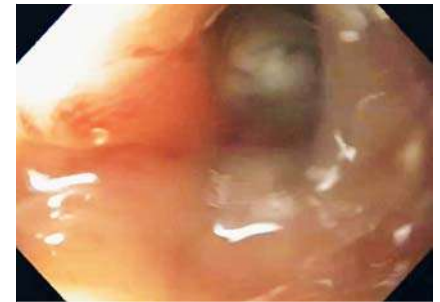
DRAINING

- Septotomy
- Endoscopic vacuum therapy (EVT)
- EID with Double pigtail stents

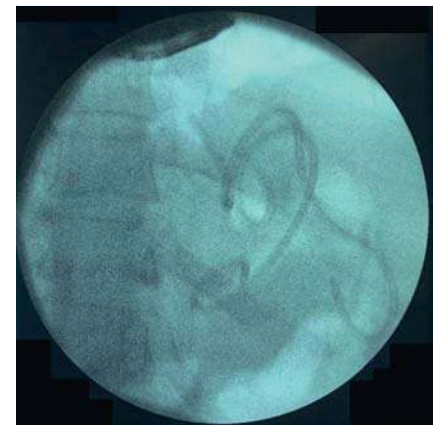
▶ **Video 1** Endoscopic techniques for post-bariatric surgery leaks and fistulas.



▶ **Fig. 1** Fluoroscopic imaging demonstrating a large perigastric fluid collection from an acute sleeve leak within the residual fundus after laparoscopic sleeve gastrectomy.



▶ **Fig. 2** Endoscopic imaging showing the leak orifice.

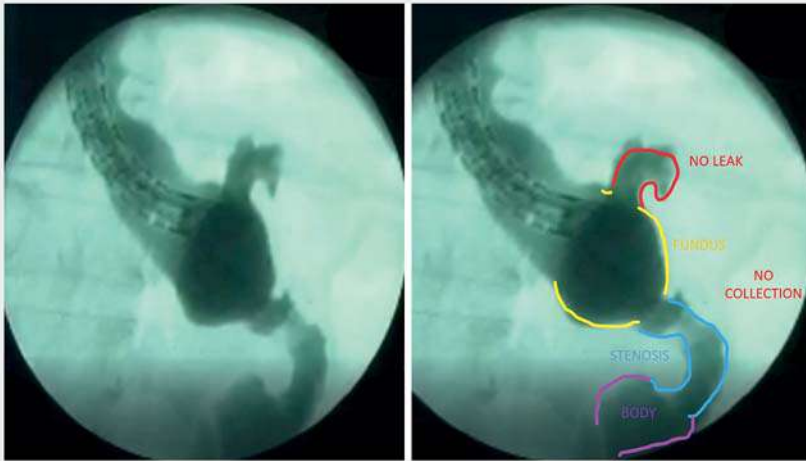


▶ **Fig. 3** Fluoroscopic imaging confirming appropriate positioning of the two double-pigtail plastic stents to achieve successful endoscopic internal drainage.

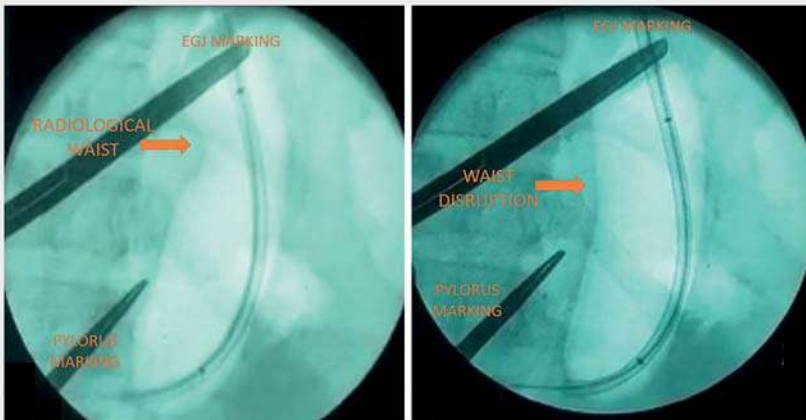
Although laparoscopic sleeve gastrectomy (LSG) is the most commonly performed bariatric surgery worldwide, postsleeve leaks may occur in up to 5.3% of patients [1]. More recently, novel endoscopic draining therapies including endoscopic vacuum therapy, septotomy, and the use of endoluminal double-pigtail stents (DPS) have been deployed [2–4]. In this video, we describe successful

endoscopic internal drainage of a perigastric sleeve leak using DPS (▶ **Video 1**). A 35-year-old woman presented to our institution 1 week after LSG with abdominal pain and fever. Initial endoscopy and fluoroscopy revealed an acute post-LSG leak in the residual fundus with purulent drainage and an associated large fluid collection (▶ **Fig. 1**, ▶ **Fig. 2**). Given these findings, the decision was made to place

two DPS (7 Fr×9cm) to achieve successful endoscopic internal drainage (▶ **Fig. 3**). The patient was discharged 3 days later without complications receiving a full liquid diet and a course of oral antibiotics. The DPS were removed 1 month after the procedure. At that time, endoscopic and fluoroscopic evaluation demonstrated resolution of the leak and the associated fluid collection (▶ **Fig. 4**). At the same time, a sleeve stenosis was observed and pneumatic balloon dilation (30mm) performed until the radiological “waist” was disrupted (▶ **Fig. 5**). After dilation, the endoscope was easily able to traverse the site of the earlier stenosis.



► **Fig. 4** Fluoroscopic imaging after removal of the double-pigtail stents, demonstrating complete resolution of the sleeve leak and associated fluid collection.



► **Fig. 5** Pneumatic balloon dilation of the sleeve stenosis showing the disruption of the “radiological waist.”

Approximately 2 months later, the patient remained asymptomatic with the diet advanced without any problems. In summary, endoscopic techniques to treat complications following bariatric surgery are feasible, safe, and effective when the correct approach is selected. In this video, we review principles and techniques of sleeve leaks and describe successful endoscopic management of an acute leak 1 week after LSG. Ultimately, endoscopic internal drainage is a well-tolerated option to achieve complete drainage of acute post-LSG leaks and col-

lections and is associated with reduced morbidity, high success rates, shorter hospital stay, and a low rate of adverse events [5].

Endoscopy_UCTN_Code_CPL_1AH_2AG

Competing interests

The authors declare that they have no conflict of interest.

The authors

Diogo Turiani Hourneaux de Moura¹, João Remi de Freitas Júnior¹, Gabriel Mayo Vieira de Souza¹, Guilherme Henrique Peixoto de Oliveira¹, Thomas R. McCarty², Christopher C. Thompson², Eduardo Guimarães Hourneaux de Moura¹

- 1 Gastrointestinal Endoscopy Unit, Gastroenterology Department, Hospital das Clínicas da Faculdade de Medicina da Universidade de São Paulo, Brazil
- 2 Gastroenterology, Hepatology and Endoscopy Division – Harvard Medical School, Brigham and Women’s Hospital, Boston, Massachusetts, USA

Corresponding author

Guilherme Henrique Peixoto de Oliveira, MD

Av. Dr Enéas de Carvalho Aguiar, 225, 6º andar, bloco 3, Cerqueira César, 05403-010 – São Paulo, SP, Brazil
guilherme.hpoliveira@hc.fm.usp.br

References

- [1] Hamid HKS, Emile SH, Saber AA et al. Customized bariatric stents for sleeve gastrectomy leak: are they superior to conventional esophageal stents? A systematic review and proportion meta-analysis. *Surg Endosc* 2021; 35: 1025–1038
- [2] de Moura DTH, Sachdev AH, Thompson CC. Endoscopic full-thickness defects and closure techniques. *Curr Treat Options Gastroenterol* 2018; 16: 386–405
- [3] Haito-Chavez Y, Kumbhari V, Ngamruengphong S et al. Septotomy: an adjunct endoscopic treatment for post-sleeve gastrectomy fistulas. *Gastrointest Endosc* 2016; 83: 456–457
- [4] Boghossian MB, Funari MP, do Monte Junior ES et al. Endoscopic septotomy for fistula after bariatric surgery. *Endoscopy* 2021; 6: 569–672
- [5] Donatelli G, Dumont JL, Cereatti F et al. Treatment of leaks following sleeve gastrectomy by endoscopic internal drainage (EID). *Obes Surg* 2015; 25: 1293–1301

Bibliography

Endoscopy
DOI 10.1055/a-1525-1661
ISSN 0013-726X
published online 2021
© 2021. Thieme. All rights reserved.
Georg Thieme Verlag KG, Rüdigerstraße 14,
70469 Stuttgart, Germany