

VIDEO CASE REPORT

Common bile duct intussusception during ERCP for stone removal

Rodrigo Silva de Paula Rocha, MD, Maurício Kazuyoshi Minata, MD,
Diogo Turiani Hourneaux de Moura, MD, MSc, Eduardo Guimarães Hourneaux de Moura, MD, PhD,
Tomazo Antonio Prince Franzini, MD, PhD

Post-ERCP adverse events occur in 6.9% of patients and mortality in 0.33%. The most common adverse events are pancreatitis (3.47%), bleeding (1.34%), sepsis (1.44%), and perforation (0.6%).¹ Rare adverse events after ERCP occur in 1% of cases and could put the patient in critical condition requiring urgent surgical intervention.^{2,3} We report the first case of a common bile duct (CBD) intussusception during ERCP for stone removal in a patient with ulcerative colitis (UC) and primary sclerosing cholangitis (PSC).

A 66-year-old man was referred for a second ERCP attempt at stone removal a week after cannulation of the CBD had failed. He had experienced jaundice and abdominal pain for the previous month, and US and CT showed cholecystolithiasis, choledocholithiasis, and dilatation of the intrahepatic bile ducts. His medical history included UC, rheumatoid arthritis, type 2 diabetes, and placement of a coronary stent after a myocardial infarction.

The CBD was cannulated with a guidewire sphincterotome (Video 1, available online at www.VideoGIE.org). The intrahepatic bile ducts showed segmental strictures and dilatation, which suggested PSC (Fig. 1). There was a

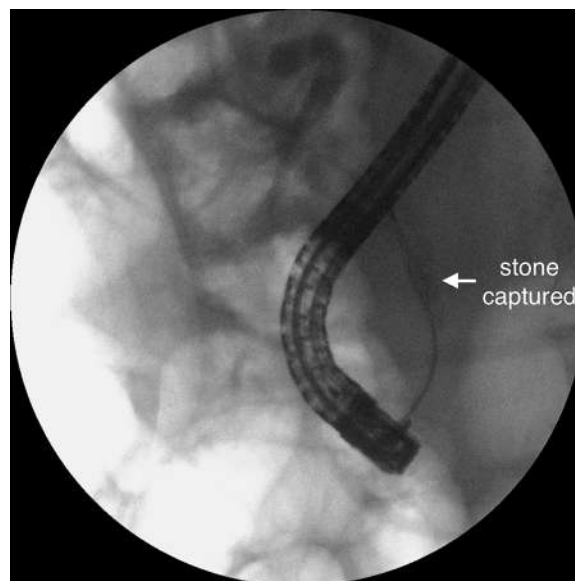

Figure 2. Basket with the gallstone captured in the middle third of the common bile duct.

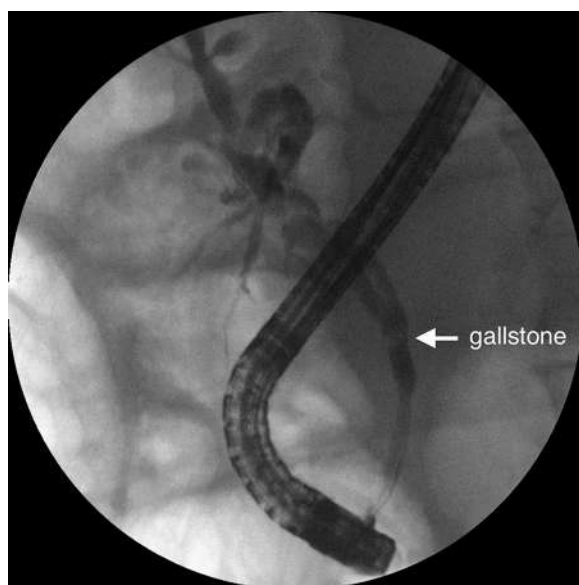


Figure 1. ERCP cholangiogram with a 7-mm gallstone in the middle third of the common bile duct, intrahepatic segmental strictures, and dilatation.

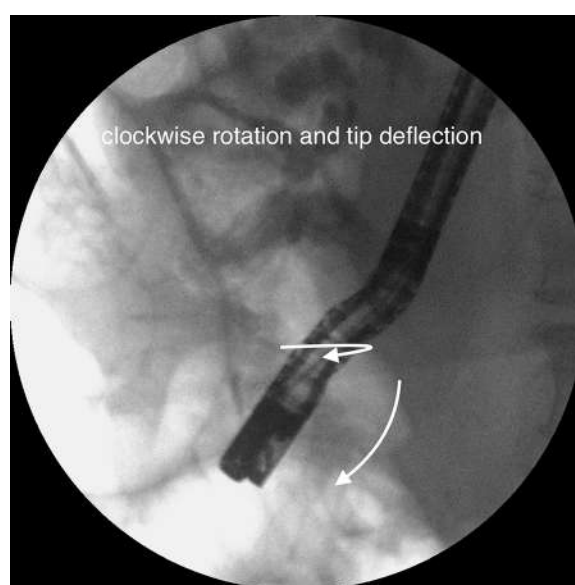

Figure 3. Combined movement of clockwise rotation, tip deflection, and endoscope pushing to remove the device with the stone.

Written transcript of the video audio is available online at www.VideoGIE.org.

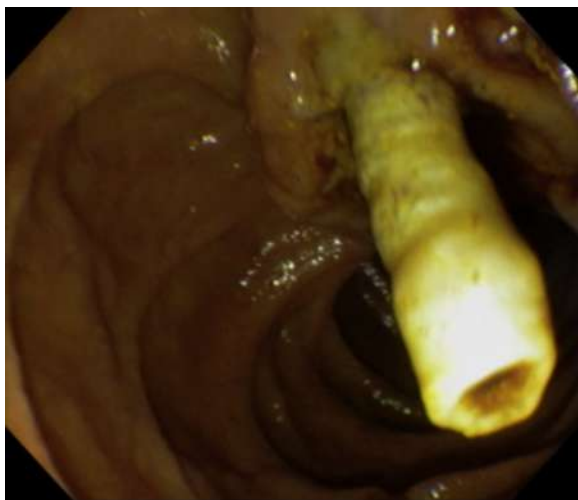

Figure 4. Common bile duct intussusception after attempt at stone removal.

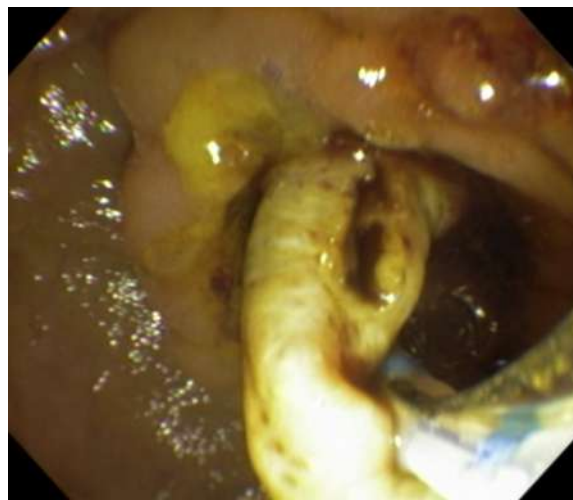


Figure 6. Everted bile duct fistulotomy access.

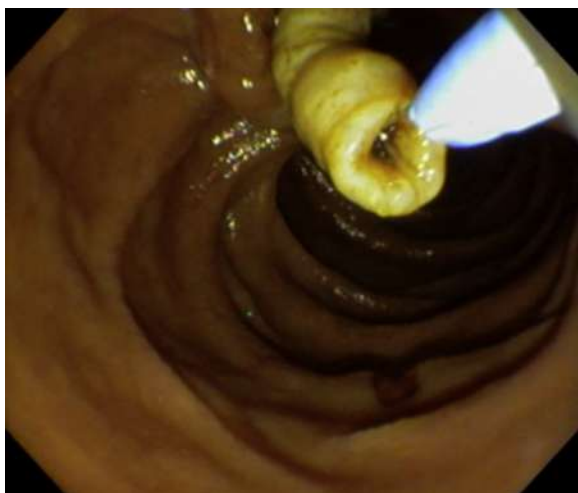

Figure 5. Cannulation attempt with guidewire sphincterotome.

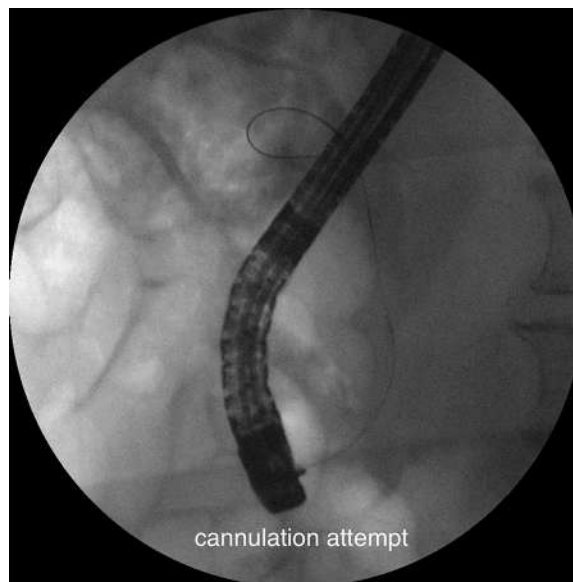

Figure 7. Cannulation attempt through the biliary access by use of guidewire sphincterotome.

single 7-mm gallstone in the mid-distal CBD, near the cystic duct implantation, with a nondilated distal bile duct. Papillotomy was performed, and the stone was captured with a basket (Fig. 2). Because the stone's largest axis became aligned with the CBD, the device was pulled back with gentle traction, and a combined movement of clockwise rotation, tip deflection, and endoscope pushing was completed (Fig. 3). The basket came out of the papilla with the stone inside it but with the biliary wall stuck around it. After maneuvers, the basket was released, but the distal CBD was everted into the duodenum (Fig. 4).

Repeated cannulation was tried with the aim of setting the CBD back into the correct position by deploying a stent. Attempts with different devices were made without success (Fig. 5). A Roth net was used to squeeze the

CBD and remove the gallstone, but cannulation failed. After surgical consultation, a 2-mm longitudinal fistula was created with a needle-knife in the superior side of the intussuscepted wall, and cannulation was attempted (Figs. 6 and 7). A cholangiogram showed extravasation of contrast material, which suggested perforation or complete rupture of the CBD (Fig. 8).

The patient underwent an exploratory laparotomy. The findings were biliary ascites and a dilated and tortuous CBD, with no damage to the wall. Cholecystectomy was performed, and a cholangiogram through the cystic duct showed a blockage in the distal CBD (Fig. 9). Biliary exploration with a Randall forceps removed the

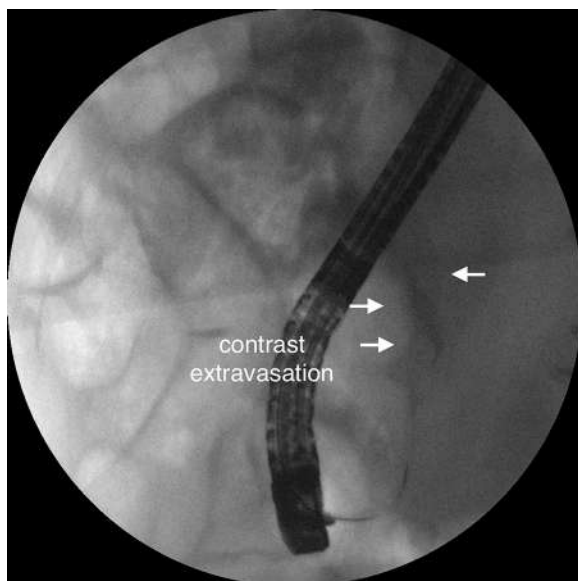


Figure 8. Extravasation of contrast material after cannulation through the biliary access, suggesting perforation or complete rupture.

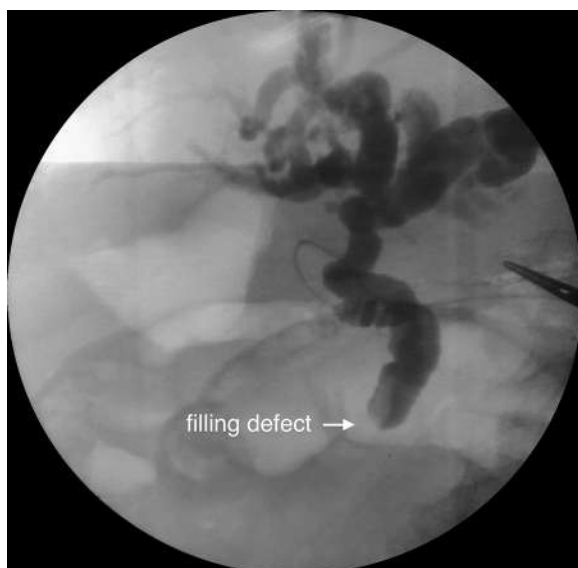

Figure 9. Intraoperative cholangiogram through cystic duct showing distal obstruction corresponding to the everted bile duct.

remaining stones, and a Roux-en-Y hepaticojejunostomy was performed.

In the intensive care unit, the patient's bilirubin levels decreased, and his condition improved. On the eighth postoperative day, he experienced melena and hemodynamic instability. An EGD revealed 4 acute gastric ulcers without high-risk stigmata. On the tenth postoperative day, he died after experiencing refractory septic shock before a surgical approach could be attempted. The post-mortem assessment showed that the cause of death was fecal peritonitis due to a perforated colonic ulcer in an area of the transverse colon affected by ischemic colitis.

Histologic study found chronic nonspecific cholangitis with wall fibrosis, periportal lymphomononuclear infiltration, and what we assumed to be a case of PSC complicated by secondary choledocolithiasis.⁴

Wall thickening created the impression of a nondilated CBD. The basket was chosen because it would allow mechanical lithotripsy.⁵ Lithotripsy seemed unnecessary after the stone was captured and the axes became aligned; however, similar diameters in a chronically inflamed bile duct led to impaction and intussusception.

An entirely new condition without previous reporting in the literature was found. After a consulting surgeon proposed a biliodigestive anastomosis, biliary access through the everted wall was the last effort at endoscopic resolution. Although surgery was successful, the patient's comorbidities were decisive for the outcome.

Prompt intervention can minimize morbidity and mortality in cases of ERCP adverse events,⁶ but prevention should be the first concern. Therefore, we reinforce the recommendation of lithotripsy before stone removal or plastic stent placement in a nondilated bile duct, especially in patients with UC and PSC.

DISCLOSURE

All authors disclosed no financial relationships relevant to this publication.

Abbreviations: CBD, common bile duct; PSC, primary sclerosing cholangitis; UC, ulcerative colitis.

REFERENCES

1. Andriulli A, Loperfido S, Napolitano G, et al. Incidence rates of post-ERCP complications: a systematic survey of prospective studies. *Am J Gastroenterol* 2007;102:1781-8.
2. Freeman ML, Nelson DB, Sherman S, et al. Complications of endoscopic biliary sphincterotomy. *N Engl J Med* 1996;335:909-18.
3. Chandrasekhara V, Khashab MA, Muthusamy VR, et al. Adverse events associated with ERCP. *Gastrointest Endosc* 2017;85:32-47.
4. Lee Y-M, Kaplan MM. Primary sclerosing cholangitis. *N Engl J Med* 1995;332:924-33.
5. ASGE Technology Committee; Adler DG, Conway JD, Farraye FA, et al. Biliary and pancreatic stone extraction devices. *Gastrointest Endosc* 2009;70:603-9.
6. Anderson MA, Fisher L, Jain R, et al. Complications of ERCP. *Gastrointest Endosc* 2012;75:467-73.

Gastrointestinal Endoscopy Unit, General Hospital of the University of Sao Paulo School of Medicine, São Paulo, Brazil.

Copyright © 2017 American Society for Gastrointestinal Endoscopy. Published by Elsevier Inc. This is an open access article under the CC BY-NC-ND license (<http://creativecommons.org/licenses/by-nc-nd/4.0/>).

<https://doi.org/10.1016/j.vgie.2017.09.003>